



Report of a Case of Pacemaker Depletion Presenting with Wide QRS Tachycardia

Geniş QRS Taşikardi ile Başvuran Kalp Piliin Tükenmesi: Runaway Pacemaker

Özgür Kaplan¹, Ertan Aydın², Sabri Demircan¹

¹İstanbul Bilim Üniversitesi Tıp Fakültesi, Kardiyoloji Anabilim Dalı, İstanbul, Türkiye

²Giresun Devlet Hastanesi, Kardiyoloji Bölümü, Giresun, Türkiye

ABSTRACT

Runaway pacemaker results from pacemaker malfunction and is characterized by sudden increases in the stimulus rate above the set upper rate limit of the pacemaker. Here we report the case of a patient with wide QRS complex tachycardia who was admitted to the emergency unit and diagnosed with runaway pacemaker.

Keywords: Arrhythmia, runaway pacemaker, wide QRS tachycardia

ÖZ

Runaway pacemaker pilin arızalı çalışmasından kaynaklı ve pil limitlerinin üstünde ani hızlarla artmasıyla karakterize bir durumdur. Bu vakamızda acil servise geniş QRS taşikardi ile başvuran runaway pacemaker'lı hastayı sunduk.

Anahtar kelimeler: Aritmi, runaway pacemaker, geniş QRS taşikardi

INTRODUCTION

Runaway pacemaker results from pacemaker malfunction and is characterized by sudden increases in the stimulus rate above the set upper rate limit of the pacemaker. The increased stimulus rate may cause life-threatening complications (1). We aimed to discuss a clinical entity with respect to the rare case of a patient with wide QRS complex tachycardia who was admitted to the emergency unit and diagnosed with runaway pacemaker.

CASE PRESENTATION

An 84-year-old male patient was admitted to another center with palpitation, dyspnea, and presyncopal complaints. Wide QRS complex tachycardia (Figure 1a) was determined, and electrical cardioversion was performed several times. The patient was referred to our center because of the recurrence of tachycardia. The patient had a 210/min heart rate and 90/70 mmHg blood pressure on admission to our emergency unit. Direct current cardioversion at 150 J energy was applied at the emergency unit because of the continuation of tachycardia despite amiodarone infusion, but tachycardia recurred following a short time of heart rate control. The patient had a history of VVI pacemaker implantation for complete atrioventricular (AV) block following 3-vessel bypass surgery for coronary artery disease before 10 years. It was learnt that the patient did not undergo any evaluation of his pacemaker for a long time. Therefore, magnet response was evaluated to check for possible battery depletion. AV complete block and asystole (Figure 1b) were observed by placing the magnet, whereas wide QRS tachycardia (Figure 1c) recurred when the magnet was removed from over the battery. The patient was followed up after urgent temporary pacemaker implantation with fastening the magnet on the battery. After maintaining clinical stabilization,

the patient was taken to the laboratory for pacemaker replacement. The skin surface of the battery pocket was washed by an antiseptic solution. The, a sterile cover was placed following the fastening of the magnet held in the antiseptic solution on the battery (Figure 1d). Consequently, the pocket was dissected, and the old battery (Cardiac Impulse - Varsal, Italy, Figure 1e) was disconnected from the lead and a new VVI pacemaker battery was connected (Medtronic - Sensia, Minneapolis, USA). The pocket was closed, and the temporary pacemaker was removed. The patient did not have any problem during the follow-up and was discharged on the next day.

DISCUSSION

An important aspect of patients with QRS tachycardia admitted to the emergency unit is ventricular tachycardia, whereas aberrantly conducted supraventricular tachycardia is observed to a lesser extent. Ventricular tachycardia based on structural disease should be mainly considered in an elderly patient who has a cardiac pacemaker, has undergone coronary artery by-pass graft CABG for CAD, and is presenting with wide QRS tachycardia. The treatment for such patients should be the same as that for VT in case of failure to discriminate SVT according to ECG criteria. As in our case, events such as incessant VT, refractory ischemia, proarrhythmia related to anti-arrhythmic drugs, QT prolongation, and electrolyte disturbance should be considered in case of early-relapsing, monomorphic, wide QRS tachycardia despite electrical cardioversion. Pacemaker-mediated tachycardia and runaway pacemaker should be considered in differential diagnosis when spikes are present before the QRS complex during tachycardia. Runaway pacemaker results from pacemaker malfunction and is characterized by sudden increases in the stimulus rate above the adjusted upper rate limit of the pacemaker (1).

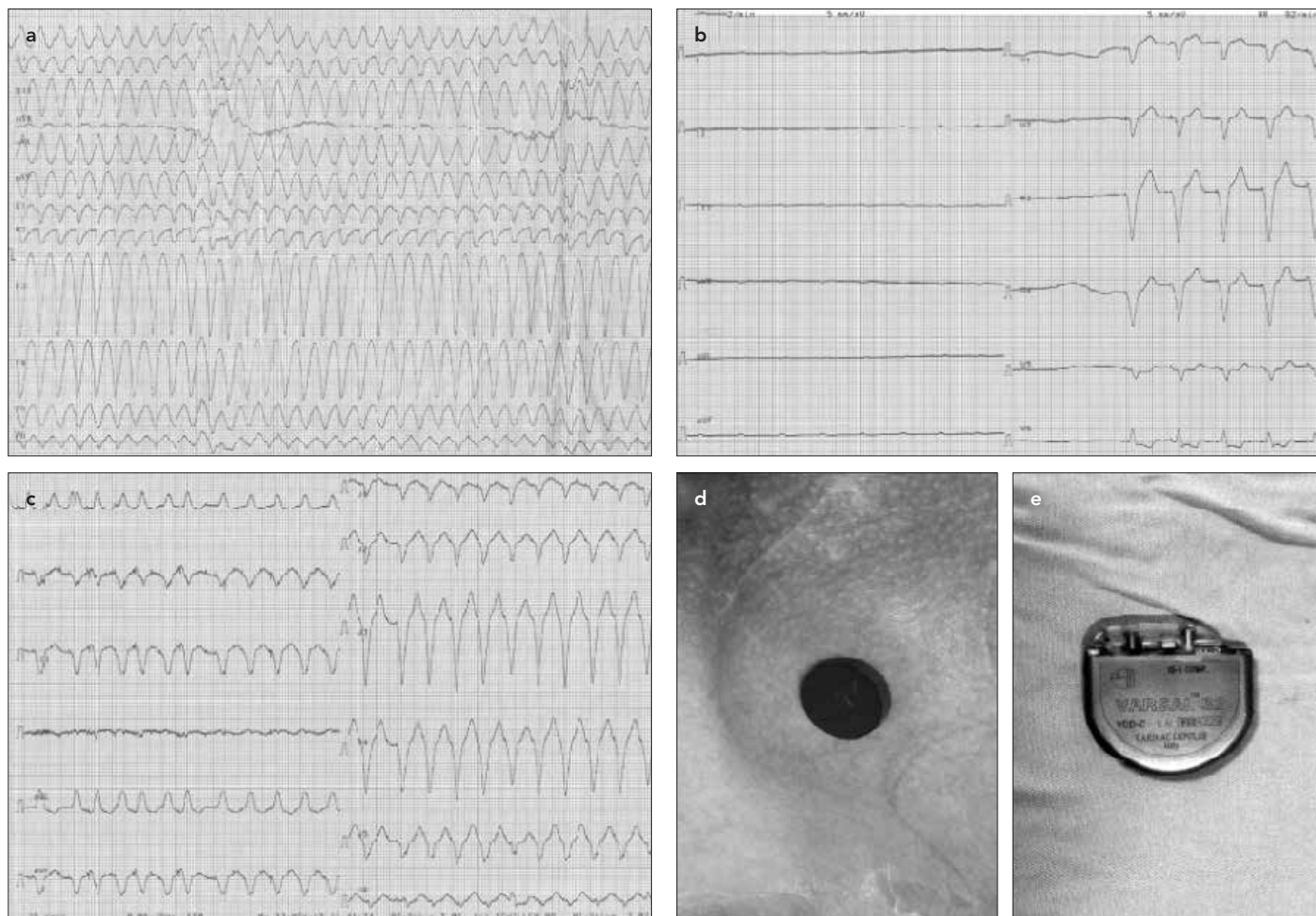


Figure 1. a-e. ECG obtained on patient admission (a). ECG obtained after magnet placement (b). Irregular ventricular capture and spikes are noticed immediately after magnet removal (c). Image before replacement performed under the magnet (d). Possible depleted battery after removal (e)

The increased stimulus rate may cause life-threatening complications (2, 3). The runaway phenomenon is mostly seen in case of a delay in the elective replacement time and excessive decline of battery voltage, particularly in old-generation pacemakers (4). ECG in cases of the typical runaway phenomenon has a slower intermittent ventricular capture or a very-high-rate pacemaker capture, which looks like an artifact. In our case, it was determined very fast regular spikes produced irregular ventricular capture in ECG records obtained immediately after magnet removal. In the follow-up, these spikes, which produced regular and fast ventricular capture and clinical tachycardia mimicking VT, were not seen clearly in ECG. Magnet response should be mainly evaluated in runaway pacemaker cases. The magnet can be occasionally ineffective or cause asystole in pacemaker dependency, as in our case. The battery should be urgently replaced or if there is an asystole response, the magnet should be applied along with a temporary pacemaker back up, as done in our case.

The old pacemaker implanted for our patient has been used in our country for a temporary period because of social security policies. The control of this pacemaker period is not possible as a result of the disappearance of manufacturer firms from marketing and impair or unavailability of control providers' programmers. The problem with our case was the disruption of control. When

making a choice between a pacemaker and ICD, which have vital importance in the treatment of patients, it is important to consider reliable, sustainable, and technologically proven firms that provide technical support worldwide. Regional and local conditions should also be considered.

CONCLUSION

Runaway pacemaker may be rarely observed, particularly in the emergency unit. It should be considered in patients with a pacemaker who present with wide QRS tachycardia. It can be easy to diagnose in patients with typical ECG or distinguishable spikes before QRS. On the other hand, runaway pacemaker should be considered in case tachycardia is similar to VT and there are relapses despite recurrent DC VT. The problem should be solved by magnet response, a temporary pacemaker, or urgent battery replacement when required.

Informed Consent: Verbal informed consent was obtained from patient who participated in this study.

Peer-review: Externally peer-reviewed.

Author Contributions: Concept - Ö.K., S.D.; Design - Ö.K., S.D.; Data Collection and/or Processing - Ö.K., E.A.; Analysis and/or Interpretation - Ö.K., E.A.; Literature Search - Ö.K., S.D.; Writing Manuscript - Ö.K., S.D.; Critical Review - Ö.K., S.D.; Other - E.A., S.D.

Conflict of Interest: No conflict of interest was declared by the authors.

Financial Disclosure: The authors declared that this study has received no financial support.

Hasta Onamı:Sözlü hasta onamı bu çalışmaya katılan hastadan alınmıştır.

Hakem Değerlendirmesi: Dış bağımsız.

Yazar Katkıları: Fikir - Ö.K., S.D.; Tasarım - Ö.K., S.D.; Veri Toplanması ve/veya İşlemesi - Ö.K., E.A.; Analiz ve/veya Yorum - Ö.K., E.A.; Literatür Taraması - Ö.K., S.D.; Yazıyı Yazan - Ö.K., S.D.; Eleştirel İnceleme - Ö.K., S.D.; Diğer - E.A., S.D.

Çıkar Çatışması: Yazarlar çıkar çatışması bildirmemişlerdir.

Finansal Destek: Yazarlar bu çalışma için finansal destek almadıklarını beyan etmişlerdir.

REFERENCES

1. Griffin J, Smithline H, Cook J. Runaway pacemaker: a case report and review. J Emerg Med 2000; 19: 177-181. [\[CrossRef\]](#)
2. Mickleby H, Andersen C, Nielsen LH. Runaway pacemaker: a still existing complication and therapeutic guidelines. Clin Cardiol 1989; 12: 412-4. [\[CrossRef\]](#)
3. Makaryus AN, Patrick C, Maccaro P. A rare case of "runaway" pacemaker in a modern CPU-controlled pacemaker. Pacing Clin Electrophysiol 2005; 28: 993-996. [\[CrossRef\]](#)
4. Ortega DF, Sammartino MV, Pellegrino GM, Barja LD, Albina G, Segura EV, et al. Runaway pacemaker: a forgotten phenomenon? Europace 2005; 7: 592-7. [\[CrossRef\]](#)