



Costal Osteochondroma Invaginating Into the Liver: A Case Report

Karaciğere İnvajine olan Kostal Osteokondrom: Olgu Sunumu

Emrah Aydın

Clinic of Pediatrics, Bahçelievler State Hospital, İstanbul, Turkey

Cite this article as: Aydın E. Costal Osteochondroma Invaginating Into the Liver: A Case Report. JAREM 2017; 7: 105-6

ABSTRACT

Here we present the case of a 14-year-old old boy with an osteochondroma, which was incidentally diagnosed and was invaginating into the capsule of the liver but not causing any symptom.

Keywords: Osteochondroma, liver, rib

ÖZ

Bu çalışmada amacımız, 14 yaşında bir erkek olguda rastlantısal saptanan, karaciğere invajine olan ancak bulgu vermeyen bir kostal osteokondrom olgusunu sunmaktır.

Anahtar kelimeler: Osteokondroma, karaciğer, kaburga

INTRODUCTION

Although rare, most cases of rib lesions are neoplastic in behavior in the pediatric age group. In the literature, osteochondromas represent 8% of rib tumors and half of benign rib tumors (1). A costal osteochondroma, which is also known as exostosis, results from the separation of the epiphyseal growth plate cartilage from the main epiphysis that causes lateral lying down of the bone (2). Most cases have been incidentally diagnosed while investigating some other pathologies.

Here we present the case of a patient who was diagnosed with osteochondroma of the rib while investigating abdominal pain.

CASE PRESENTATION

A 14-year-old boy was admitted to the emergency department with a complaint of abdominal pain for the past 3 months. He was investigated and found to have a calcified mass located in the liver on ultrasonography. After referral, he was found to be exposed to a traffic accident 4 years ago. His physical examinations revealed nothing. There was no tenderness or swelling in the area where pain was felt. His X-ray revealed calcification in the right lobe of the liver. Computed tomography and magnetic resonance imaging of the abdomen were performed (Figure 1). The calcification was found to originate from the 10th rib. There was no fracture or fissure found on the rib. In addition, there was no hemorrhage around the liver. The calcified lesion seemed to have invaginated into the capsule of the liver, but no damage was found on the liver. Osteochondroma was suspected as the radiological diagnosis. Percutaneous biopsy was per-

formed, and the pathological diagnosis was a normal mature bone marrow material that was an osteochondroma. Because it does not cause any discomfort to the patient and the operation itself has many risks, a follow-up decision was taken. The patient has been followed up for the past 6 months and has been free of any symptoms. Consent was obtained from parents.

DISCUSSION

Primary rib tumors may arise from the bone, cartilage, bone marrow and surrounding structures. Fibrous dysplasia, enchondromas, osteochondromas, aneurysmal bone cysts, and eosinophilic granulomas are the most common benign pathologies arising from the bone or cartilage in childhood. Osteochondromas, being the most common benign tumors of the rib, are usually found in the anterior region of the costo-chondral junction (3). They mostly affect children and young adults, generally before the age of 20 years. They present as a painless, very slowly growing, hard outgrowth. In our case, the patient was 14 years old. He had a dull feeling of pain. On follow-up, it was seen that the growth was not rapid.

Khosla and Parry (2) have presented a case of a costal osteochondroma causing pneumothorax. In the literature, there are 2 more cases due to complications of osteochondromas. In our patient, the lesion itself was very near to the liver. It seemed to have invaginated into the capsule of the liver. There was no hemorrhage or symptom. Because the operation itself had many risks due to the need for mobilization of the liver, a follow-up decision seemed logical.



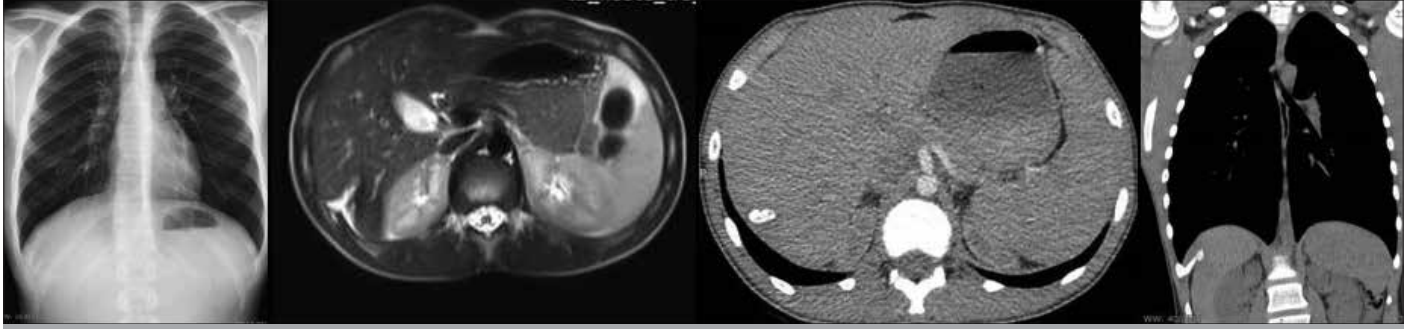


Figure 1. Radiologic imagings of the lesions

CONCLUSION

Because osteochondromas are benign in nature, when not complicating, they can be followed-up safely.

Informed Consent: Written informed consent was obtained from patients' parents who participated in this study.

Peer-review: Externally peer-reviewed.

Conflict of Interest: No conflict of interest was declared by the author.

Financial Disclosure: The author declared that this study has received no financial support.

Hasta Onamı: Yazılı hasta onamı bu çalışmaya katılan hastanın ailesinden alınmıştır

Hakem Değerlendirmesi: Dış bağımsız.

Çıkar Çatışması: Yazar çıkar çatışması bildirmemiştir.

Finansal Destek: Yazar bu çalışma için finansal destek almadığını beyan etmiştir.

REFERENCES

1. Waller DA, Newman RJ. Primary bone tumours of the thoracic skeleton: an audit of the Leeds regional bone tumour registry. *Thorax* 1990; 45: 850-5. [\[CrossRef\]](#)
2. Khosla A, Parry RL. Costal osteochondroma causing pneumothorax in an adolescent: a case report and review of the literature. *J Ped Surg* 2010; 45: 2250-3. [\[CrossRef\]](#)
3. Tateishi U, Gladish GW, Kusumoto M, Hasegawa T, Yokoyama R, Tsuchiya R, et al. Chest wall tumors: radiologic findings and pathologic correlation: part 1. Benign tumors. *Radiographics* 2003; 23: 1477-90. [\[CrossRef\]](#)