



Incomplete Bladder Duplication in an Asymptomatic Pregnant Female

Asemptomatik Gebe Bir Kadında İnkomples Mesane Duplikasyonu

Erdal Alkan¹, Miraç Turan¹, Altuğ Semiz², Mevlana Derya Balbay¹

¹Department of Urology, Şişli Memorial Hospital, İstanbul, Turkey

²Department of Gynecology and Obstetrics, Şişli Memorial Hospital, İstanbul, Turkey

Cite this article as: Alkan E, Turan M, Semiz A, Balbay MD. Incomplete Bladder Duplication in an Asymptomatic Pregnant Female. JAREM 2017; 7: 89-91.

ABSTRACT

Bladder duplication is a very rare congenital malformation of the urinary system, which is classified as complete or incomplete. This malformation is usually associated with other anomalies, which may be urogenital or nonurogenital. We present a case of incomplete sagittal bladder duplication in an asymptomatic adult female who became pregnant and delivered a healthy baby.

Keywords: Bladder, female, pregnancy, bladder duplication

ÖZ

Mesane duplikasyonu üriner sistemin nadir görülen konjenital malformasyonlarından biri olup komplet ve inkomples olarak sınıflandırılır. Bu malformasyon genellikle ürolojik ve non-ürolojik olabilen diğer anomalilerle birlikte bulunur. İnkomples sagittal mesane duplikasyonu olan ve hamile kalarak sağlıklı bir çocuk doğuran asemptomatik erişkin bir kadın olgusunu sunduk.

Anahtar Sözcükler: Mesane, kadın, gebelik, mesane duplikasyonu

INTRODUCTION

Incomplete bladder duplication (BD) is an extremely rare congenital abnormality of the urinary system and is usually associated with other genitourinary anomalies (1, 2). We present a case of incomplete sagittal BD in an asymptomatic adult female who became pregnant and delivered a healthy baby.

CASE PRESENTATION

A 31-year-old female who wanted to have a baby was admitted to the gynecology clinic. She was referred to the urology department due to a suspected bladder abnormality during routine gynecological examination. The patient had no lower urinary symptom. On physical examination, a single urethral meatus was detected. Urinary ultrasound showed two hypoechogenic structures, which communicated with each other in the pelvis. Cystoscopy was performed, which showed a single urethra. However, there was a sagittal ledge of tissue connecting the anterior and posterior walls of the bladder approximately 2 cm from the bladder neck, dividing the bladder cavity into right and left parts. The ureteral orifices were in their normal positions on either side. Voiding cysto-urethrography confirmed the presence of these two communicating structures (right and left parts), which lied adjacent to each other in the sagittal plane. Cystogram showed no vesico-ureteral reflux, but congenital diastasis of the pubic symphysis was detected in voiding cysto-urethrography (Figure 1). To further

delineate the nature of the bladder, magnetic resonance imagine (MRI) of the abdomen and pelvis was performed, and it was observed that the bladder was separated into two parts by a sagittal muscular septum (Figure 2a, b). Written informed consent was obtained from patient who participated in this case. The patient has been followed up without any symptom for 4 years, during which she has delivered a healthy baby after getting pregnant with assisted reproductive technology.

DISCUSSION

Bladder duplication is a rare congenital malformation of the urinary system, which was classified as complete or incomplete by Abrahamson in 1961 (3). Complete duplication is defined as the presence of two bladders and two separate urethras, whereas incomplete duplication is defined as the presence of two bladders and one common urethra. Based on the axis of the septum, BD is also classified as sagittal or coronal. Two bladders lie side by side and are separated by a fibromuscular wall in sagittal duplication, in which each bladder receives the ureter of the ipsilateral kidney. Conversely, two bladders lie one behind the other and are separated by a fibromuscular wall that runs obliquely in a posterosuperior to anteroinferior plane in coronal duplication, in which there are two separated urethras (3, 4). Although the exact etiology of BD is unknown, a few hypotheses have been proposed by Abrahamson (3, 4).

This study was presented in 11th National Endourology Congress in Turkey (23-26 April, 2015, Antalya, Turkey).
Bu çalışma 11. Ulusal Endüroloji Kongresi'nde sunulmuştur (23-26 Nisan 2015, Antalya, Türkiye).



Address for Correspondence / Yazışma Adresi: Erdal Alkan
E-mail: eralkan@hotmail.com

Received Date / Geliş Tarihi: 04.11.2015 Accepted Date / Kabul Tarihi: 01.01.2016
© Telif Hakkı 2017 Gaziosmanpaşa Taksim Eğitim ve Araştırma Hastanesi. Makale metnine

www.jarem.org web sayfasından ulaşılabilir.
© Copyright 2017 by Gaziosmanpaşa Taksim Training and Research Hospital. Available on-line at www.jarem.org
DOI: 10.5152/jarem.2017.981

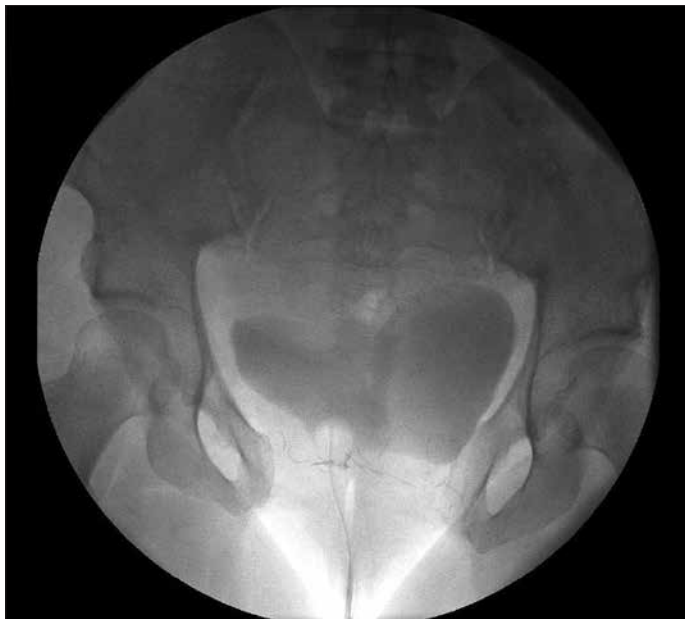

Figure 1. Voiding cysto-urethrography showing incomplete bladder duplication

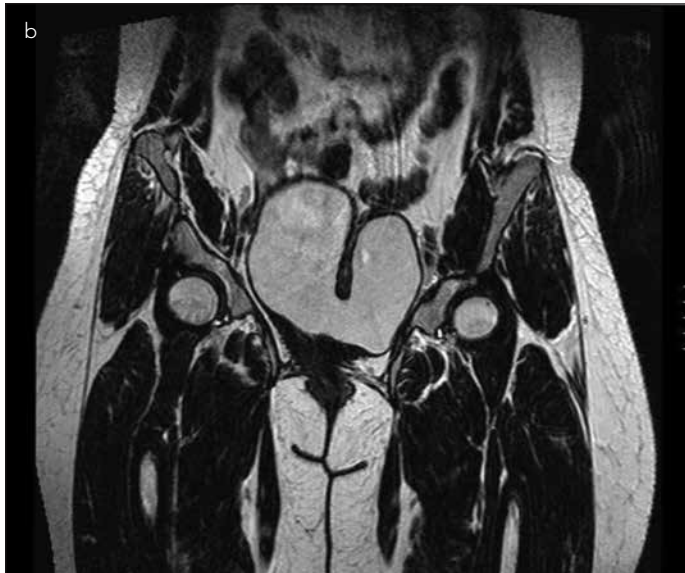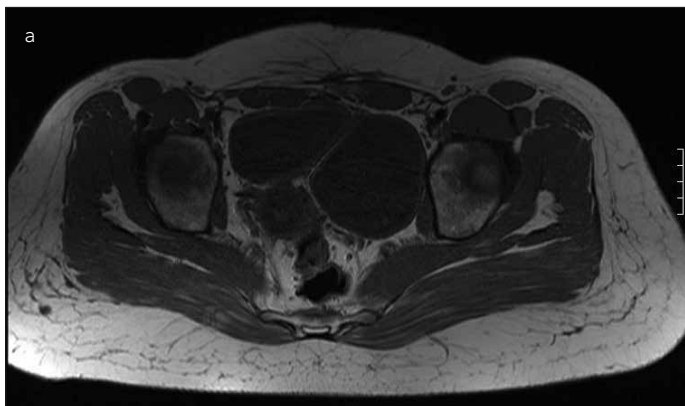


Figure 2. a, b. MRI appearance of incomplete sagittal bladder duplication on a transverse plane (a), MRI appearance of incomplete sagittal bladder duplication on a coronal plane (b)

Lower urinary system abnormalities are usually diagnosed either at birth or during childhood when US examination, for any reason, is performed into the urologically asymptomatic patient or when causes of urinary tract infections are evaluated. However, there are two cases with BD that remained asymptomatic for more than 5 decades in the English literature (5, 6). Our patient was relatively older at the time of diagnosis since she had no symptoms related to BD.

Bladder duplication is usually associated with other anomalies, which may be urogenital or nonurogenital. Complete or partial duplication of the urethra, diphallus, bifid scrotum, duplication of the glands, congenital urethral valves, unilateral renal dysplasia, unilateral gonadal agenesis, duplication of the vagina, and various fistula formations between the urethra, vagina, and rectum are the most detected urogenital malformations associated with BD (1, 2, 4-7). Associated nonurogenital congenital anomalies include duplication of the lower gastrointestinal tract, spina bifida, duplication of the spine, meningocele, meningomyelocele, diastasis of the pubic symphysis, anorectal atresia, and imperforate anus (2, 4-6). Our patient had congenital diastasis of the pubic symphysis, which was asymptomatic, as well.

The treatment should be individualized (8). Incomplete duplications may not require surgical interventions if the patient remains asymptomatic (2, 6). There are two main goals of treatment in an asymptomatic patient with incomplete BD: renal preservation and prevention of urinary infections (2, 9). Because our patient remained asymptomatic until 31 years of age, surgical intervention was not planned. She has successfully conceived with assisted reproductive technology and uneventfully delivered at the term. To our knowledge, this is the first case of a patient with BD who conceived and delivered without any abnormality in the English literature.

CONCLUSION

Incomplete BD may be without any resultant vesico-ureteral reflux or voiding dysfunction. In addition, conception is not compromised when the genital tract and hormonal status are normal. Female patients with BD may become pregnant and may eventually have a healthy baby.

Informed Consent: Written informed consent was obtained from patient who participated in this study.

Peer-review: Externally peer-reviewed.

Author Contributions: Concept – E.A., M.T., A.S., M.D.B.; Design – E.A., M.T., A.S., M.D.B.; Supervision – E.A., M.t., A.S., M.D.B.; Resources – M.T., A.S.; Materials - T.Ç.; Data Collection and/or Processing – E.A., M.T., A.S.; Analysis and/or Interpretation – E.A., M.D.B.; Literature Search – M.T., A.S.; Writing Manuscript – E.A., A.S.; Critical Review – M.D.B.

Conflict of Interest: No conflict of interest was declared by the authors.

Financial Disclosure: The authors declared that this study has received no financial support.

Hasta Onamı: Yazılı hasta onamı bu çalışmaya katılan hastadan alınmıştır.

Hakem Değerlendirmesi: Dış bağımsız.

Yazar Katkıları: Fikir – E.A., M.T., A.S., M.D.B.; Tasarım – E.A., M.T., A.S., M.D.B.; Denetleme – E.A., M.t., A.S., M.D.B.; Kaynaklar – M.T., A.S.; Mal-

zemeler - T.Ç.; Veri Toplanması ve/veya İşlemesi – E.A., M.T., A.S.; Analiz ve/veya Yorum – E.A., M.D.B.; Literatür Taraması – M.T., A.S.; Yazıyı Yazan – E.A., A.S.; Eleştirel İnceleme – M.D.B.

Çıkar Çatışması: Yazarlar çıkar çatışması bildirmemişlerdir.

Finansal Destek: The authors declared that this study has received no financial support.

REFERENCES

1. Metzger R, Schuster T, Stehr M, Pfluger T, Dietz HG. Incomplete duplication of the bladder. *Eur J Pediatr Surg* 2004; 14: 203-5. [\[CrossRef\]](#)
2. Awasthi NK, Goel H, Mahapatra R, Pal D. Incomplete bladder duplication with multiple congenital anomalies: A rare presentation. *Urol Ann* 2015; 7: 88-90. [\[CrossRef\]](#)
3. Abrahamson J. Double bladder and related anomalies: Clinical and embryological aspects and a case report. *Br J Urol* 1961; 33: 195-8. [\[CrossRef\]](#)
4. Gajbhiye V, Nath S, Ghosh P, Chatterjee A, Haldar D, Das SK. Complete duplication of the urinary bladder: An extremely rare congenital anomaly. *Urol Ann* 2015; 7: 91-3. [\[CrossRef\]](#)
5. Karpathakis N, Vasileiou G, Fasoulakis K, Heretis I. First case of complete bladder duplication in the coronal plane with concomitant duplication of the urethra in an adult male. *Case Rep Urol* 2013; 2013: 638125. [\[CrossRef\]](#)
6. Taneja R, Singh DV. Incomplete transverse vesical septum: An unusual congenital anomaly. *Indian J Urol* 2012; 28: 193-5. [\[CrossRef\]](#)
7. Ciftci AO, Senocak ME, Büyükpamukçu N, Hiçsönmez A. Complete duplication of the bladder and urethra: A case report and review of the literature. *J Pediatr Surg* 1995; 30: 1605-6. [\[CrossRef\]](#)
8. Mirshemirani AR, Sadeghyian N, Mohajerzadeh L, Molayee H, Ghafari P. Diphallus: Report on six cases and review of the literature. *Iran J Pediatr* 2010; 20: 353-7.
9. Coker AM, Allshouse MJ, Koyle MA. Complete duplication of bladder and urethra in a sagittal plane in a male infant: case report and literature review. *J Pediatr Urol* 2008; 4: 255-9. [\[CrossRef\]](#)