



# Thoracic Myelomeningocele with Hydrocephalus And Chiari Type 2 Malformation: A Case Report

Hidrocefali ve Chiari Tip 2 Malformasyonunun Eşlik Ettiği Torakal Myelomeningosel: Olgu Sunumu

Gökhan Canaz, Kaan Baturay, Nur Topyalın, İzzet Durmuşalioğlu, Ali Osman Akdemir

Clinic of Brain Surgery, University of Health Sciences Haseki Training and Research Hospital, İstanbul, Turkey

**Cite this article as:** Canaz G, Baturay K, Topyalın N, Durmuşalioğlu İ, Akdemir AO. Thoracic Myelomeningocele with Hydrocephalus And Chiari Type 2 Malformation: A Case Report. JAREM 2017; 7: 99-101.

## ABSTRACT

Neural tube defects (NTDs) are multifactorial midline abnormalities that occur during the neurulation process in embryogenesis. Myelomeningocele is an important abnormality that may indicate the necessity of an emergency intervention. Although myelomeningocele can be seen throughout the all spinal axis, the areas with the most common and least common localizations are the lumbosacral region and thoracic region, respectively. The most common co-abnormalities have been reported to be hydrocephalus and Chiari type 2 malformations. There are some differences in the management regarding to the order and the timing of the surgery in myelomeningocele associated with hydrocephalus and Chiari malformations. Here we discuss our management of a rare case of thoracic myelomeningocele associated with hydrocephalus and Chiari type 2 malformation.

**Keywords:** Myelomeningocele, hydrocephalus, Chiari malformation type 2, spina bifida

## ÖZ

Nöral tüp defektleri (NTD) embriyonal gelişimin 4.haftasında nörolasyon aşamasında meydana gelen multifaktöryel, orta hat anomalileridir. Myelomeningosel de bu grup acil girişim endikasyonu olabilen önemli anomalilerden biridir. Myelomeningosel, tüm spinal aks boyunca görülebilmekle birlikte en sık lumbosakral, en nadir de torakal yerleşimli olarak görülür. En sık eşlik edilen anomali ise hidrocefali ve Chiari tip 2 malformasyonu olarak bildirilmektedir. Myelomeningosele eşlik eden hidrocefali ve Chiari malformasyonlarına müdahale zamanlaması ve sıralaması konusunda literatürde pek çok yaklaşım bulunmaktadır. Yazımızda hidrocefali ve Chiari tip 2 malformasyonunun eşlik ettiği nadir bir torakal myelomeningosel olgusunu ve bizim tedavi yaklaşımımızı sunduk.

**Anahtar kelimeler:** Myelomeningosel, hidrocefali, Chiari malformasyonu tip 2, spina bifida

## INTRODUCTION

Myelomeningocele is a saculation of the meninx and spinal cord through a vertebral defect that develops because of a closure defect of the posterior neuropore, which is the latest phase of neurulation in the third and fourth weeks of gestation. Genetic predisposition, in addition to environmental factors, is included in the etiology (1, 2). Its frequency is 0.7–0.8 in 1000 live births. Although myelomeningocele can be seen throughout the all spinal axis, the areas with the most common and least common localizations are the lumbosacral region and thoracic region, respectively (1, 3). The spinal level of myelomeningocele sac and prognosis are highly correlated. The most common additional malformations in these patients are hydrocephalus and Chiari Type II abnormality (4).

## CASE PRESENTATION

A thoracic lesion that was thought to be myelomeningocele sac was detected during the prenatal ultrasound examination, which was expected to be the second live birth from the second preg-

nancy of a 28-year-old mother. The high probability of paraplegia was explained to the family; the option of termination of the pregnancy was discussed with the family, and a decision was made to continue the pregnancy. Upon physical examination of the newborn baby, which was born through normal delivery in the 36<sup>th</sup> gestational week, an open myelomeningocele sac measuring approximately 5x4 cm in the thoracic region was seen. Neurological examination revealed no motor deficits. An emergency operation was planned because an open sac was prone to the risk of infection. During the preoperative tests, hydrocephalus and Chiari type 2 anomaly were encountered in the brain tomography of the patient (Figure 1). The herniation level was not within the surgery limits, and we decided to follow the Chiari anomaly without surgery. The baby was planned to be surgically treated for hydrocephalus, and myelomeningocele sac excision, closure of the skin defect, and placement of a ventriculoperitoneal (VP) shunt were planned (Figure 2a).

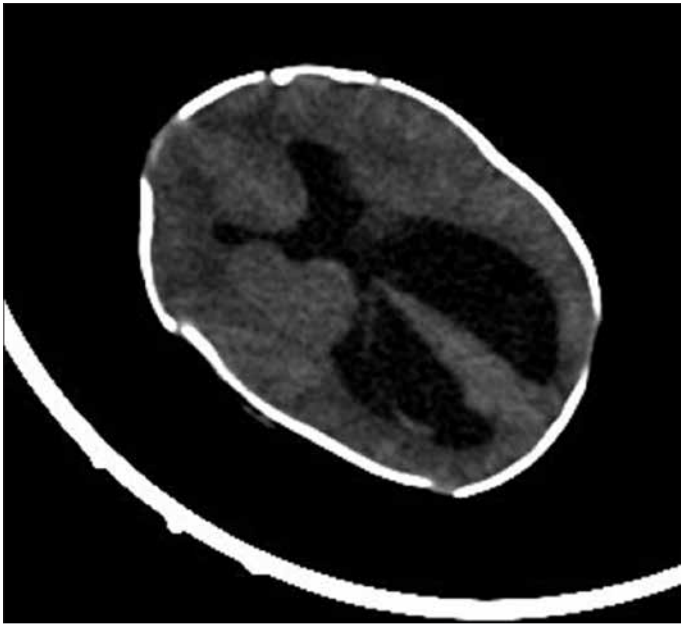
The baby was taken to the operating room in the 16<sup>th</sup> postnatal hour. First, a VP shunt was placed. Subsequently, the baby was

*Bu çalışma Türk Nöroşirürji Derneği 29. Bilimsel Kongresi'nde sunulmuştur, 17-21 Nisan 2015, Antalya, Türkiye.  
This study was presented at the Turkish Neurosurgical Society 29<sup>th</sup> Scientific Congress, 17-21 April 2015, Antalya, Turkey.*

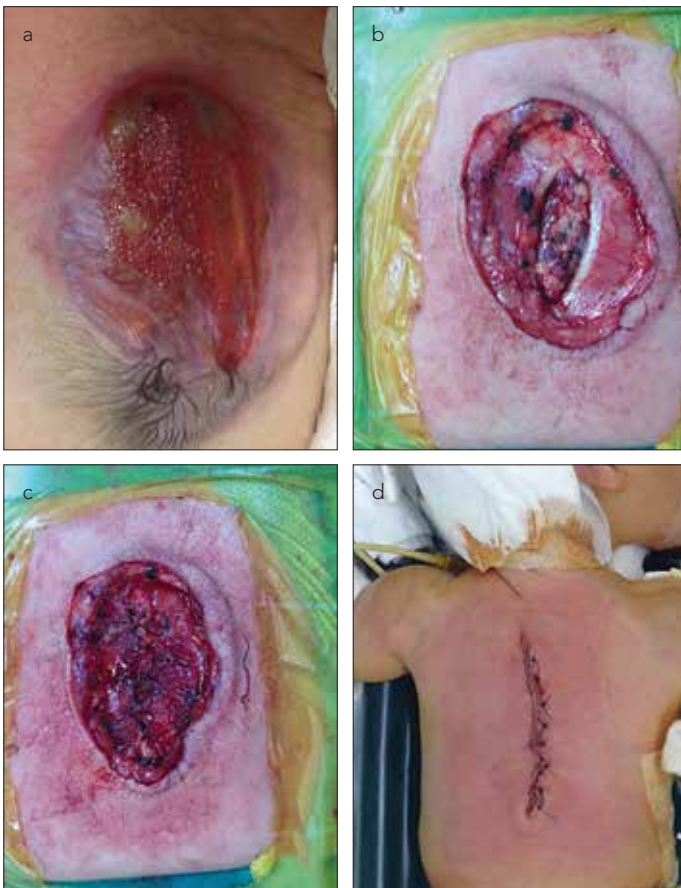

Address for Correspondence / Yazışma Adresi: Gökhan Canaz  
E-mail: gokhancanaz@gmail.com

Received Date / Geliş Tarihi: 12.01.2016 Accepted Date / Kabul Tarihi: 11.04.2016  
© Copyright 2017 by Gaziosmanpaşa Taksim Training and Research Hospital. Available on-line at www.jarem.org  
© Telif Hakkı 2017 Gaziosmanpaşa Taksim Eğitim ve Araştırma Hastanesi. Makale metnine www.jarem.org web sayfasından ulaşılabilir.  
DOI: 10.5152/jarem.2017.1041



**Figure 1.** Computer tomography image showing ventricular dilatation



**Figure 2. a-d.** (a) Open myelomeningocele sac. (b) Closed dura, 5-0 suture material used. (c) Closed fascia on the dura, 4-0 absorbable material used. (d) Closed skin defect, 3-0 prolene suture used

placed in the prone position. The epithelial zone around the sac was incised through a full-thickness skin incision and was totally excised. Fascia and dura were seen. Following the circular exci-

sion of the skin around the neural plaque, a neural tube was developed. The dura was closed water-tight using 5-0 suture material (PERMA-HAND® Silk Suture, Ethicon, Summerville, NY, USA) (Figure 2b). Following this, both sides of the fascia were elevated and closed on the dura using 4-0 absorbable material (Figure 2c). The subcutaneous tissue was dissected on both the sides. The subcutaneous tissue was sutured using a 4-0 absorbable material (Coated VICRYL (polyglactin 910) Suture, Ethicon, Summerville, NY, USA), and the skin was closed using a 3-0 polypropylene suture (PROLENE Polypropylene Suture, Ethicon, Summerville, NY, USA), (Figure 2d). Postoperatively, the patient was followed-up in the neonatal intensive care unit. The patient was discharged on the 7<sup>th</sup> postoperative day. An informed written consent was obtained from the patient's family for scientific presentation.

## DISCUSSION

Neural tube defects (NTDs) have been classified in various different systems, one of which classifies NTDs simply as open or closed defects according to the closure of the defect. Open neural tube defects are NTDs in which the cerebrospinal fluid (CSF) frequently leaks through the present defect, which develops secondary to failed closure of the neural tissue during primary neurulation. Closed NTDs, on the other hand, are abnormalities encountered with a clinical picture of completely closed neural tissue, localized under an epithelialized layer, which occurs because of the failure of secondary neurulation (1, 5). Myelomeningocele is the most well-known malformation that is encountered as an open NTD and defined as a condition of the presence of CSF leakage, which necessitates immediate intervention, if possible, due to the high risk of infection.

Myelomeningocele can be observed at any level through the spinal axis. Studies have reported that the areas with the most common localizations are the lumbosacral and lumbar regions and the area with the least frequent localization is the thoracic region (1, 2). The level of the lesion was correlated with the severity and prognosis of the deficit. The prognosis worsened with the elevation of the level. Because the frequency of the lesion is more common in the lumbar and lumbosacral regions, the most common complication encountered is bladder dysfunction. The most common accompanying abnormalities have been reported to be, in descending order of frequency, hydrocephalus and Chiari type 2 malformations (2, 6). Although the frequencies of the development of hydrocephalus and Chiari type 2 malformation are similar, the rate of intervention for Chiari abnormalities is much lower than that of hydrocephalus. On the other hand, because the presence of hydrocephalus may be symptomatic and may even cause deterioration of the condition, a VP shunt becomes necessary in nearly 85% of the cases with accompanying hydrocephalus to myelomeningocele. Indications for intervention for Chiari abnormalities are having symptoms such as postnatal stridor, bradycardia, and dysphagia due to the dysfunction of bulbus and cranial nerves exiting from this level. Babies in the neonatal period are thought to tolerate this abnormality slightly better than hydrocephalus (7).

The timing of the intervention for myelomeningocele is debatable. Waiting up to 72 hours can be allowed, particularly in cases of intact sac integrity, and this period is thought to aid in the

psychological preparation of both the patient and the family and better assessment of the patient preoperatively and during the early postnatal period. On the other hand, more satisfactory results have been reported in terms of motor development in cases in which early intervention is performed (1, 8). In addition, early intervention results in some advantages such as a shorter duration of hospitalization and shorter duration of antibiotic use (2).

Another issue of discussion is the order of operations in cases of coincidence of myelomeningocele and hydrocephalus. Sac repair is suggested to be performed in the first 36 hours; some studies have suggested that a shunt should be placed in a second operation, while some studies have demonstrated that the risk of ventriculitis and shunt infection decreases in cases in which sac repair and VP shunt placement is performed in the same operation (2, 7, 8). We considered that the best option is to decide according to the condition of the patient and the circumstances. We decided to place the VP shunt first because we thought that the ventricle anatomy would have changed due to the possible draining of CSF. Following this, we planned sac repair in the same session.

## CONCLUSION

Myelomeningocele is the best known neural tube defect with variable prognosis, which is affected by localization and other accompanying abnormalities. Accurate planning and treatment based on the individual needs of the patients are highly important.

**Informed Consent:** Written informed consent was obtained from the parents of the patient who participated in this study.

**Peer-review:** Externally peer-reviewed.

**Author Contributions:** Concept – K.B., G.C.; Design – G.C., İ.D.; Supervision – A.O.A., K.B.; Resources – A.O.A., G.C., N.T.; Materials – N.T., İ.D.; Data Collection and/or Processing – G.C., N.T., İ.D.; Analysis and/or Interpretation – A.O.A., K.B.; Literature Search – G.C.; Writing Manuscript – G.C.; Critical Review – A.O.A., N.T.; Other – İ.D.

**Conflict of Interest:** No conflict of interest was declared by the authors.

**Financial Disclosure:** The authors declared that this study has received no financial support.

**Hasta Onamı:** Yazılı hasta onamı bu çalışmaya katılan hastanın ailesinden alınmıştır.

**Hakem Değerlendirmesi:** Dış bağımsız.

**Yazar Katkıları:** Fikir – K.B., G.C.; Tasarım – G.C., İ.D.; Denetleme – A.O.A., K.B.; Kaynaklar – A.O.A., G.C., N.T.; Malzemeler – N.T., İ.D.; Veri Toplanması ve/veya İşlemesi – G.C., N.T., İ.D.; Analiz ve/veya Yorum – A.O.A., K.B.; Literatür Taraması – G.C.; Yazıyı Yazan – G.C.; Eleştirel İnceleme – A.O.A., N.T.; Diğer – İ.D.

**Çıkar Çatışması:** Yazarlar çıkar çatışması bildirmemişlerdir.

**Finansal Destek:** Yazarlar bu çalışma için finansal destek almadıklarını beyan etmişlerdir.

## REFERENCES

1. N A. Myelomeningosel. In: Ozek MM BM, Erşahin Y, Mutluer MS, editor. Pediatrik nöroşürji. Ankara Türk nöroşürji derneği; 2014. p. 263-74.
2. Frey L, Hauser WA. Epidemiology of neural tube defects. *Epilepsia* 2003; 44: 4-13. [CrossRef]
3. Ersahin Y, Barcin E, Mutluer S. Is meningocele really an isolated lesion? *Childs Nerv Syst* 2001; 17: 487-90. [CrossRef]
4. McLone DG, Knepper PA. The cause of Chiari II malformation: a unified theory. *Pediatr Neurosci* 1989; 15: 1-12. [CrossRef]
5. L W Harris WJO. Open neural tube defects In: G T Tindall PRC, D L Barrow, editor. *The practice of neurosurgery*. Baltimore: Williams and Wilkins; 1996. p. 2779-89.
6. Kumar R, Singh SN. Spinal dysraphism: trends in northern India. *Pediatr Neurosurg* 2003; 38: 133-45. [CrossRef]
7. Onel MY, Ozdemir R, Kahilogullari G, Yurttutan S, Erdeve O, Dilmen U. The effect of surgery time on prognosis in newborns with meningocele. *J Korean Neurosurg Soc* 2012; 51: 359-62. [CrossRef]
8. Tamburrini G, Frassanito P, Iakovaki K, Pignotti F, Rendeli C, Murolo D, et al. Myelomeningocele: the management of the associated hydrocephalus. *Childs Nerv Syst* 2013; 29: 1569-79. [CrossRef]