



The Benign Strictures of the Esophagus

Ferda Nihat Köksoy, Doğan Gönüllü

Clinic of General Surgery, Gaziosmanpaşa Taksim Training and Research Hospital, İstanbul, Turkey

ABSTRACT

The old procedure known as the treatment of esophageal stricture is the pushing of “string of whale” similar to a modern dilator. The first written record is from the 17th century by an Italian anatomist Fabricius ab Aquapendente who lived in Bejaia, a city in Algeria; he used a wax bougie in place of a dilator. The first bougienage procedure in esophageal strictures was published in 1821. The normal esophageal diameter is between 20–30 mm, and if the diameter is less than 12 mm, the dysphagia symptom becomes evident. The symptoms disappear when the diameter becomes larger than 15 mm. Peptic esophagitis (70%–80%), anastomotic strictures, trauma, radiation treatment, and caustic burn were the frequent causes of stricture. The physical examination did not offer a clue in terms of cause of stricture. It is important to evaluate the nutrition status of a patient. The barium contrast passage completed by endoscopic evaluation are important in diagnostics; by a sequence in the function of grading of stricture, an initial treatment with aggressive proton pump inhibitor (PIP) is preferred. After the bougie and balloon dilatation and in cases with persistent strictures, corticosteroid injection and self-expanded stents will be used. The expanding stents will never be used as the first option and will be used only after multiple dilatations. Although PIP and bougie dilatations are used with good results in simple strictures, the complex strictures, particularly in which the guiding wire does not progress through strictures, a percutaneous gastrostomy (PEG) is performed and the stricture is retrogradely aborted. The complications of dilatation procedure are up to 0.1%–0.3% perforation and bleeding of less than 0.2%. In difficult strictures, covered and uncovered metallic or nonmetallic stents are used. Despite careful indications, there are many complications such as stent migration, severe thoracic pain, bleeding, perforation, gastroesophageal reflux, stent obstruction, and fistula development. Endoscopic stricturoplasty and surgical resection are alternative treatments in the treatment of difficult strictures. In many studies, the progressive dilatation up to 40–60 F is with less complication, and 85% of the patients improved; however, 30% of these patients were recurrent, and 60% of the patients without anti-secretory treatment were recurrent after one year of follow-up. The success of surgical resection is related to the experience of surgical center and is generally approximately up to 77%. The requirement of dilatation after surgery is between 1% and 43%, and one to two sessions are needed. (*JAREM 2016; 6: 1-14*)

Keywords: Esophageal strictures, bougie dilatation, balloon dilatation

BENIGN STRICTURES OF THE ESOPHAGUS

The sensation of food sticking or getting hung up in the esophagus (dysphagia) is a problem that has been encountered for many ages. The oldest procedure known for the treatment of esophageal stricture is the pushing of “string of whale” down the esophagus, which is similar to today’s dilator. The oldest written record is from the 17th century by the Italian anatomist Fabricius ab Aquapendente who lived in Bejaia, a city in Algeria, and who used a wax bougie as a dilator (1). The bougienage procedure for the dilatation of esophageal strictures was first published in 1821 (2).

The normal esophageal diameter is between 20 mm and 30 mm, but if the diameter is less than 12 mm, dysphagia symptoms begin to occur (3, 4). The esophageal diameter must be at least 15 mm for symptomatic healing to occur.

ETIOLOGICAL CAUSES

1. Peptic esophageal stricture: Approximately 70–80% of benign strictures (5, 6) are peptic strictures due to reflux (4). In addition, it is reported that the occurrence of peptic strictures has decreased with the common use of PPI drugs over the past several years. However, strictures associated with anastomosis, radiation, phototherapy, caustic burn, and nasogastric tube have begun to increase (7).

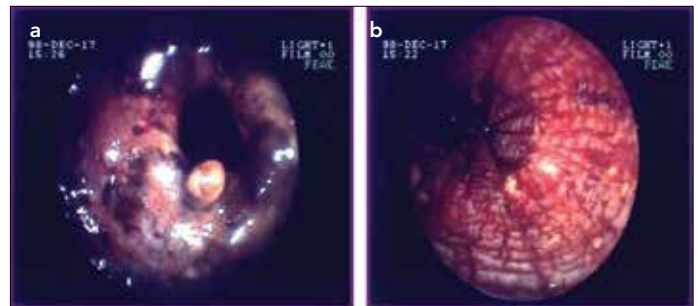
2. The rate of strictures associated with anastomosis (6) has been reported to vary between 10% and 42% (8, 9). Because the rate of peptic strictures has decreased with the use of PPI drugs, the rate of benign esophageal stricture occurrence has increased (7). The causes of these strictures are ischemia, reflux, and anastomotic leakage. Although they are reported to be observed more frequently in anastomoses performed with a stapler, some researchers have suggested that there is no difference. The technique for preparing the gastric tube is also questioned in terms of ischemia risk. To obtain a solution through dilatation is more difficult than in other strictures.
3. Radiation therapy: Radiotherapy applied in the thorax and neck can lead to esophageal stricture (10). If radiotherapy and chemotherapy are given together, the rate of stricture occurrence can increase to 25–40% (11). Because the rate of peptic strictures has decreased with the use of PPI drugs, the rate of benign esophageal stricture occurrence has increased (7). Head-neck radiotherapy, which affects the esophageal lumen and the muscles related to swallowing, particularly the hypopharynx and cricopharyngeal muscles, causes strictures that can be treated and dilated more difficultly. Even if dilated, problems in swallowing function can go on due to impaired swallowing coordination. The devel-



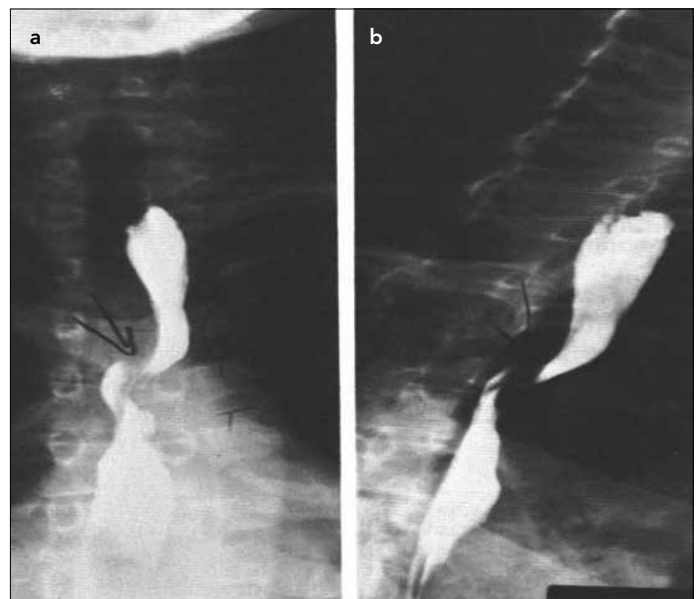opment of these strictures above the esophagus is also one of the reasons for the failure of treatment. In some patients, a stent is required to be placed above the cricopharyngeal level, and is generally considered as a contraindication. Even if a stent is placed, patients always feel as if there is a foreign body present (7).

4. The risk of the development of a stricture is above 30% after photodynamic therapy performed for Barrett esophagus (9, 12).
5. Esophageal injuries, foreign bodies that are swallowed, and caustic burns can cause strictures in the late period. Endoscopy must be performed within the first 48 hours in order to determine the stage of a corrosive burn (Picture 1). Because stage IIB (20–30% of stricture) and stage III (90% of stricture) corrosive injuries can cause chronic stricture, the insertion of a nasogastric tube under the guidance of an endoscope without the formation of a stricture or the prevention of a stricture with silicon, silastic, or rubber stents, has been successfully performed in some cases (14). Performing dilatation in the first 3–4 weeks after a corrosive injury increases the risk of perforation. Endoscopic monitorization must be continued for the possible risk of cancer development. Strictures due to a foreign body depend on the time during which the foreign body stays in the esophagus. Objects including alkaline substances, such as an alkaline battery, lead to lichefaction necrosis. Here mucosal damage typically begins about one hour after swallowing the battery and affects the entire wall of the esophagus within four hours (15). When a nasogastric tube is removed after a long stay in location, a stricture may develop (7). Moreover, a stricture can develop after endoscopic mucosal resection (especially if 3/4 of the diameter is affected) (16).
6. External compression is caused by lung malignancies, mediastinal masses, grown thyroid, bone protrusion, or a compression of the heart/aorta. Dysphagia lusoria occurs due to compression from the right subclavian artery, which passes behind the esophagus (Picture 2). Its incidence is between 0.6% and 1.8%, and it can be asymptomatic until adult age, although this is an anomaly. Progressive dysphagia develops against solid food. If its symptoms are severe, ligation of the right subclavian artery on the exit of the aorta and its anastomosis to the right carotid artery may be performed (17).
7. Schatzki ring: This is a hard mucosal scar that narrows the lumen in the lower esophagus at the squamocolumnar junction. It always exists with a hiatal hernia and is associated with reflux. Most Schatzki rings heal with 50–60 Fr dilatation in a single session. Sometimes, rings coexisting with inflammation and ulceration can act as a peptic stricture and recur after dilatation. In this case, additional procedures may be needed (13).
8. Drug-induced esophagitis: Alendronate, iron sulfate, non-steroid anti-inflammatories (NSAIDs), phenytoin, potassium chloride, quinidine, tetracycline, and ascorbic acid (18) cause local acid or alkaline burn, severe reflux, or local hyperosmolarity, and thus, damage. In terms of drug-induced strictures, 3/4 occur at the middle narrowing of the esophagus (at the level of the left atrium).

9. Endoscopic sclerotherapy has a risk of esophageal complications at the rate of 0–53%. It was found that it led to strictures at a rate of 12% in a series that included 250 cases (19).
10. Upper esophageal web (Plummer-Vinson syndrome): Esophageal webs are thin membranous lesions that are generally located in the segment 2–4 cm proximal region. These strictures are generally 2–3 cm long and are composed of partially scarificated inflammatory changes. It is thought that they are formed due to the accumulation of reflux content under the cricopharyngeus muscle during sleep. Sometimes, they are one of the components of Plummer-Vinson syndrome (including dysphagia, iron deficiency anemia, splenomegaly, and oropharyngeal inflammation). Because of the risk of the development of oropharyngeal or esophageal cancer in a 10-year period, they must be followed up. During endoscopy, webs can be ruptured without noticing. Although spontaneous recovery can be expected through iron support, dilatation and biopsy will be necessary most of the time (15).
11. Congenital reasons are quite rare (1 in 25000 births). Although rare, the presence of tracheal cartilage remnants in the esophagus and osteophytes at the C5 and C6 levels can



Picture 1. Corrosive esophageal burns (with the permission of Dr. Türker Bulut, Istanbul University, Medical Faculty, Department of General Surgery)



Picture 2. Dysphagia lusoria (with the permission of Dr. Türker Bulut, Istanbul University, Medical Faculty, Department of General Surgery).

lead to dysphagia. Forestier's disease (diffuse idiopathic spinal hyperostosis) is also another rare cause of dysphagia (15).

12. Chronic graft-versus-host disease includes gastrointestinal complications, which occur in 50% of patients 3–12 months after bone marrow transplantation applied in leukemia treatment. The rate of esophageal involvement is approximately 13–33% of cases and can be observed as strictures narrowing in the proximal region, or as a web, ring, or generalized mucosal damage. Dilatation may be necessary as well as immunosuppressive treatment (15).
13. Crohn disease displays esophageal involvement at a rate of between 1.8% and 6.5% of cases. Strictures cover the distal 1/3 of the esophagus and tend to be longer than 1 cm. Sulfasalazine and corticosteroids can be helpful for healing the symptoms (15).
14. Alkaline reflux that develops after gastric resection.
15. Infectious esophagitis: candida, herpes simplex, cytomegalovirus (CMV), human immunodeficiency virus (HIV) syphilis, and candidiasis (4).
16. Collagen vascular diseases: scleroderma, systemic lupus erythematosus (SLE), and rheumatoid arthritis (4).
17. Dermatological disorders: pemphigus vulgaris, benign mucous membrane (cicatricial) pemphigoid, epidermolysis bullosa dystrophica, and tylosis (4).
18. Idiopathic eosinophilic esophagitis.
19. Autoimmune causes.

PATHOPHYSIOLOGY

Peptic esophageal strictures (PESs) are a sequela of esophagitis associated with gastroesophageal reflux (GER) and generally occur at the squamocolumnar junction, which is 1–4 cm long.

Two important factors play a role in the development of peptic esophageal strictures:

- A dysfunctional or deficient lower esophageal sphincter (LES): In one study, compared to a healthy control group or cases with mild reflux, the mean LES pressure was found to be lower in PES patients. The value of LES was detected to be lower than 8 mmHg (20 mmHg in the control group), while the mean pressure was calculated as 4.9 mmHg (20).
- Impaired esophageal clearance and esophageal motility disorders: In the same study as above, motility disorder was found in 64% of the patients (20).

Other possible factors in the development of peptic esophageal strictures are:

- Hiatus hernia: The prevalence of hiatus hernia has been found to be 10–15% in the general population, 42% in patients with reflux but without esophagitis, 63% in patients with esophagitis, and 85% in patients with a stricture. These rates suggest that hiatus hernia may play an important role in the development of PES.
- Acid and pepsin secretion: The levels of acid and pepsin have been detected to be the same in PES patients and in patients with esophagitis who are matched in terms of age and gender.

This suggests that acid and pepsin secretion may not be a major factor. However, some authors believe that alkaline reflux plays a role.

- Gastric emptying: There is no concrete evidence for delayed gastric emptying to play a role in the development of PES.

EPIDEMIOLOGY

Because of the long duration of reflux symptoms, PES is a disease that is generally seen in patients with advanced ages. It is seen 2–3 times more commonly in men than in women. Compared to Asian and African people, the prevalence of PES is 10 times higher among Caucasians. On the other hand, in a retrospective study conducted recently, similar rates were found for Africans and Caucasians (9). In this study the authors evaluated Africans and Caucasians in terms of GER and grade, reflux-induced esophageal ulcer, and hiatus hernia and found that they had similar rates. However, they demonstrated that nausea/vomiting and heartburn behind the sternum due to erosive esophagitis and its complications were less prevalent among Caucasians (10).

Gastroesophageal reflux affects 40% of the adult population in the USA. Peptic esophageal stricture develops approximately in 7–23% of untreated GER patients.

Gastroesophageal reflux is seen in 70–80% of PES patients. Strictures develop at a rate of 10% as a postoperative complication and at a rate of 5% in cases involving the swallowing of a corrosive substance.

With the use of proton pump inhibitors (PPI), the frequency of PES and the need for dilatation have gradually decreased.

MORTALITY/MORBIDITY

There is no increase in mortality in PES unless malignancy and/or perforation develops in the location of the stricture. Morbidity, however, is at significant level, including:

- Pulmonary aspiration;
- Stricture due to food that is not well-chewed (food bolus);
- Barrett esophagus and its complications;
- Perforation occurring during dilatation.

HISTORY OF DISEASE

- Peptic stricture can present with heartburn behind the sternum, dysphagia, odynophagia, food getting hung up in the esophagus, loss of weight, and chest pain.
- Progressive dysphagia with solid food is the most common cardinal symptom (21). This condition can develop and also affect liquid food. Pulmonary findings secondary to food or acid aspiration, especially an atypical presentation of chronic cough, can be seen too. Of the patients with peptic esophageal strictures, 25% do not have a history of heartburn. Furthermore, heartburn can disappear with the progression of peptic stricture.
- Approximately 2/3 of patients with adenocarcinoma developing due to Barrett esophagus have a history of long-term heartburn.

- Abnormal motor activity in achalasia can produce sensitivity to heartburn.

IMPORTANT POINTS RELATED TO DYSPHAGIA

- Obstruction is generally felt at the lesion level or above it.
- Dysphagia beginning with solid and liquid food at the same time primarily suggests a motor disorder such as achalasia or collagen vascular disease.
- Dysphagia secondary to a Schatzki ring is generally intermittent and non-progressive.
- Dysphagia with solid and liquid food developing in early period of disease may suggest achalasia, which plays a role in the etiology of PES.
- Benign strictures of the esophagus generally progress with dysphagia, which has a slow and insidious course (over months and years) and causes minimal weight loss.
- Malignant esophageal strictures progress with rapidly developing dysphagia (over weeks and months) and lead to significant weight loss.
- It is important to know whether the patient has received a drug that causes esophagitis.
- The presence of collagen vascular disease or immune-suppression in patients must be investigated.

PHYSICAL EXAMINATION

Physical examination often does not provide a cue for the cause of dysphagia. However, it is important to detect the patient's nutritional condition.

Patients with collagen vascular disease may have joint abnormalities, calcinosis, telangiectasis, sclerodactylia, and rash.

Hoarseness, posterior oropharyngeal erythema, diffuse dental erosions, wheezing, or epigastric tenderness can be observed in patients with atypical GER.

Left supraclavicular lymphadenopathy (Virchow's nodule) can be found in patients with adenocarcinoma at the gastroesophageal junction.

LABORATORY ANALYSES

Complete blood count: Despite normal results in general, anemia may be detected due to bleeding associated with cancer or severe esophagitis.

Liver tests: Although normal results are generally found, abnormalities may be observed due to metastasis of cancer.

Comprehensive metabolic panel: These tests are used for investigating the nutritional condition of patients, particularly patients with weight loss.

IMAGING PROCESSES

Barium esophagography:

This is used for obtaining a basic image before medical treatment and endoscopy. It can provide information on the number, localization, length and diameter of lesions, whether the wall of

the esophagus is regular or not, the lumen diameter, and the presence of any other lesion in the esophagus (tumor, web, diverticula, hiatal hernia, etc.) (i.e., a route map).

The data obtained must be completed with endoscopic findings.

The data obtained from passage graphy for lesions such as a diverticula or paraesophageal hernia will be valuable for improving the safety of endoscopic examination, whose complication risk increases in these diseases.

In ring-shaped peptic strictures larger than 1 cm, the sensitivity of esophagography for the detection of strictures can be higher than that of endoscopy.

This technique has 100% sensitivity for strictures with a diameter smaller than 9 mm and 90% sensitivity for strictures with a diameter larger than 10 mm. The diameter of the lumen can be measured by swallowing 1.5 mm diameter radiopaque barium tablets (even if the tablet gets hung up, it can still dissolve).

Thoracic radiography (PA and lateral): This must be performed for revealing whether the stricture results from an external compression or not.

CT examination: This is used for staging strictures that occur due to malignancy. The accuracy rate is 60–69% for detection of the depth of tumor invasion and 82% for the detection of spreading to other organs.

Endoscopic ultrasound (EUS): EUS is the most appropriate method for determining the local invasion depth of malignancy (92%).

OTHER EXAMINATIONS

24-hour esophageal pH monitoring: This is used for the evaluation of patients whose symptoms continue despite treatment with PPI drugs or fundoplication.

Esophageal manometry: This is preoperatively used for investigating the presence of severe motility disorder in patients who are suspected to have motility disorder and/or that will undergo anti-reflux surgery.

Esophagogastroduodenoscopy (EGD): EGD is used for the confirmation of esophageal stricture diagnosis, investigation of the evidence of esophagitis, the elimination of malignancy, biopsy supply, brush cytology, and treatment. If there is no extra suspect in the barium passage graphy, EGD is generally applied before dilatation and is more sensitive than barium esophagography with regard to the detection of mucosal lesions that can be missed.

When thin endoscopes are used, annular strictures larger than 1 cm can be overlooked, especially in patients who have undergone sedation.

Esophageal strictures can be put into two groups for planning treatment: simple and complex strictures (22).

Simple strictures:

- The esophageal lumen allows the passage of a normal endoscope.
- They are straight.

- They are shorter than 2 cm.

Complex strictures:

- The esophageal lumen does not allow the passage of a normal endoscope.
- They are tortuous.
- They are longer than 2 cm and are irregular.

HISTOLOGICAL FINDINGS

The initial histological findings of peptic esophageal strictures include edema, cellular infiltration, basal cell hyperplasia, and vascular changes with mildly increased type III collagen.

Peptic irritation can cause progressive inflammation and ulcer involving submucosa and muscularis mucosae if not treated. This can result in a stricture associated with damage in the muscular layer and intrinsic nervous system and type I collagen accumulation.

MEDICAL TREATMENT

Diet

Although anti-reflux precautions and changes in lifestyle are recommended, there are no studies showing that they affect strictures yet. However:

- Patients should avoid fatty and spicy foods, alcohol, tobacco, chocolate, and peppermint;
- They should eat small and frequent portions of food and they should chew slowly and well;
- They should avoid taking meals two or three hours before bedtime;
- They should lose weight;
- Dental health should be completely ensured.

In conventional treatment, mechanical dilatation is emphasized much more and coexisting esophagitis is not mentioned sufficiently. However, many studies have demonstrated that aggressive acid suppression with PPI drugs is very useful in both the initial and long-term treatment of esophageal strictures. PPI (omeprazole, lansoprazole, rabeprazole, pantoprazole, and esomeprazole) drugs inhibit the H⁺/K⁺ ATPase enzyme system on the secretory surfaces of the parietal cells of the stomach and decrease gastric acid secretion.

- In a study that included 64 patients, a scoring system for dysphagia was developed. This system was associated with the diameter of the stricture at a rate of 30% and esophagitis and other factors at a rate of 70% (23). The dysphagia score displayed parallelism with the diameter of the stricture only in cases in which the esophageal lumen was shorter than 5 mm. In other cases, independently of the stricture diameter, the dysphagia worsened with increased esophagitis (19).
- In the study conducted by Smith et al. (24) on 366 patients randomized considering recurrence and who required re-dilatation following drug usage, they demonstrated that 20 mg omeprazole per day was superior to 300 mg ranitidine taken twice a day (recurrence requiring re-dilatation was at the rates of 30% and 46% in a year, respectively; $p < 0.01$) (25).

- In the study performed by Marks et al. (26) for the same purpose, it was revealed that 20–40 mg omeprazole per day was more effective than 150–300 mg ranitidine taken twice a day (recurrence requiring re-dilatation was at the rates of 41% and 73%, respectively; $p < 0.07$). In addition, omeprazole gave better results in terms of relieving dysphagia and healing esophagitis.
- On the contrary, Swarbrick et al. (21) and Silvis et al. (25) found no significant difference among re-dilatation rates in a year.
- In the cost analysis of esophageal stricture treatment, PPI treatment was found to be more effective than the use of H₂ blockers.

The use of PPI drugs reduces the risk of recurrence and re-dilatation (21, 25, 26).

The risks that can increase with the use of PPI drugs for a long time are:

1. Increased bacterial colonization and increased enteric infections;
2. Impairment in fat, vitamin B12, and zinc absorption;
3. Hypergastrinemia and gastric carcinoid tumors;
4. Fundus polyps;
5. Atrophic gastritis, intestinal metaplasia;
6. Hip fracture and pneumonia;
7. Production of N-nitrosamine in the stomach (27).

STANDARD TREATMENT

In benign strictures of the esophagus, first bougie or balloon dilatation, then corticosteroid injection in cases resistant to treatment, and, if it still continues, expandable stent insertion may be performed. The placement of stents must never be used as the first step of treatment and should only be performed after several dilatation sessions (6). Utrecht University, which is very experienced with complex esophageal strictures, has developed an algorithm (Figure 1) (6). Surgical treatment must be considered when no success is obtained through other procedures (5).

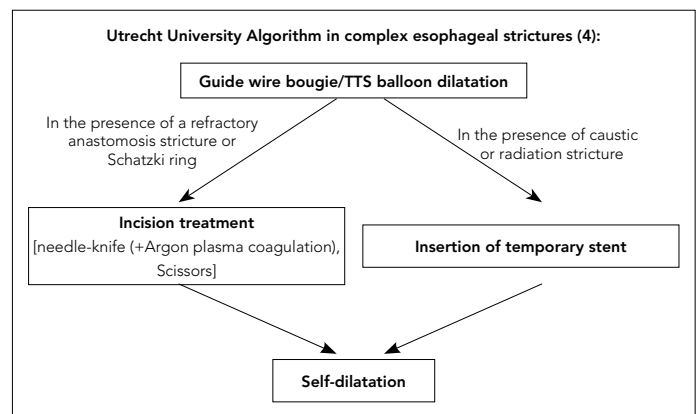


Figure 1. Treatment algorithm in complex strictures
TTS: through-the-scope

ENDOSCOPIC DILATATION

In this section, the endoscopic modalities used for peptic esophageal strictures will be reviewed. The choice of dilators and the technique depend on many factors, particularly on the characteristics of the stricture, the patient's tolerance, and the surgeon's experience and preference.

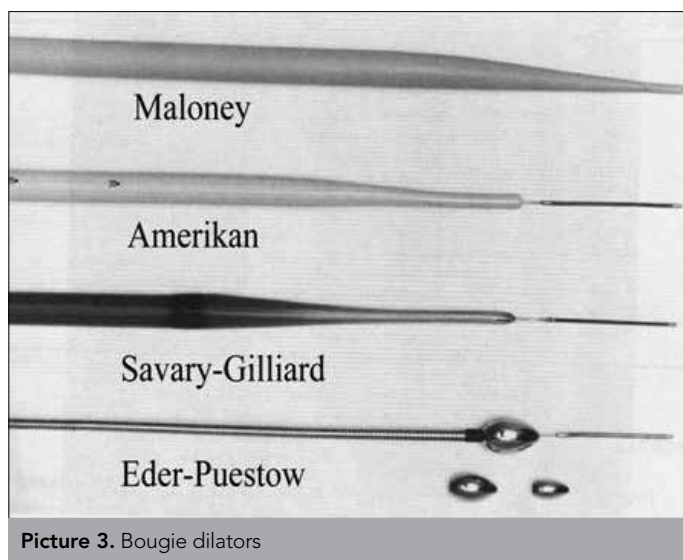
Bougie systems progressively dilate the stricture from the proximal end to the distal end at the longitudinal and radial planes. On the contrary, balloon systems simultaneously transmit the force of dilatation to the whole length of the stricture at the radial plane and reduce the stress of rupture (Picture 3) (24).

Comparison of bougies and balloons: There is still no clear evidence about the superiority of bougie and balloon procedures over each other. Both techniques have their advantages and disadvantages and typically the endoscopist will prefer one over the other. Some characteristics are: Bougies can be used repeatedly, are more economical, and can provide dilatation to the extent of their diameters by applying force in both the longitudinal and radial planes. On the other hand, balloon dilators allow dilatation without removing the endoscope and allow passage through narrower strictures (because they are placed on catheters with thinner diameters). However, even if they are inflated at the maximum level, they cannot reach the expansion provided through bougies (6).

The diameters of the dilators: Balloons are expressed in millimeters and bougies are expressed as conventional French gage (3F=1 mm). The diameters of esophageal bougies vary between 6 mm (18F) and 20 mm (60F), while the diameters of balloons vary between 5 mm and 20 mm. Balloons have 3 inflation diameters (for instance, "10, 11, and 12 mm" or "14, 15, and 16 mm") (7).

Three types of dilators are used for endoscopic dilatation:

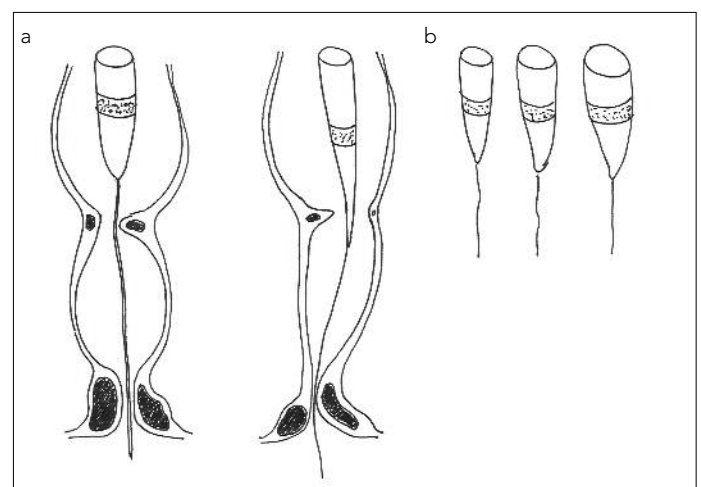
- Mercury-filled bougies, e.g., Maloney (conic-tipped) or Hurst (round-tipped) dilators:
- Their diameters are larger than 10–12 mm; they are not complicated and they are indicated for simple strictures.



Picture 3. Bougie dilators

- They can easily be used without any need for fluoroscopy guidance.
- They require no or only minimal sedation.
- Patient can perform their own bougienage at home. Self-dilatation is an effective technique, but it is difficult for a patient to feel ready for it and to swallow the dilator. The procedure must be begun by a physician who should also perform the first dilatation. Then, patients must be taught how to do it themselves. Most patients can generally keep the lumen open by performing dilatation once or for several times in a day. But some patients cannot adapt this process and want to be operated on (7).
- Wire-guided polyvinyl bougies, e.g., Savary-Gilliard, Eder-Puestow, and American dilators:
- They are made of relatively harder plastic in a conical shape. They are preferred for longer, narrower, and more irregular strictures.
- Fluoroscopy can be needed according to the situation.
- They can be used repeatedly and their diameters vary from 5 mm to 20 mm.
- They can cause trauma on the laryngeal wall while withdrawing and they are uncomfortable for the patient.
- American dilators are bougies processed with barium for a better fluoroscopic view. They are shorter and less conical. The Savary type, which is easier to use, is preferred more frequently (25).
- A flexible and transparent bougie that is consistent with the standard endoscope has been developed. It has three dilatation steps and it allows repeating dilatations with direct view (28). It is a mechanical dilator about which experience is limited.
- Mechanical dilatation

While applying a Maloney bougie, the bougie is prepared in accordance with the diameter of the stricture observed through the



Picture 4. a, b. (a) Passing a guide wire through esophageal strictures, (b) providing dilatation with a bougie (drawn by Dr. Doğan Gönüllü)

endoscope. After the endoscope is removed, it is passed through the passage blinded. The endoscopist performs bougienage by making a prediction considering the presence of a resistance to the bougie while passing through the passage and the presence of blood on the bougie after removing. The absence of any resistance and blood shows that the diameter of the bougie is small according to the diameter of stricture and that a bougie with a larger diameter is needed. Several dilators can be applied in one session (29).

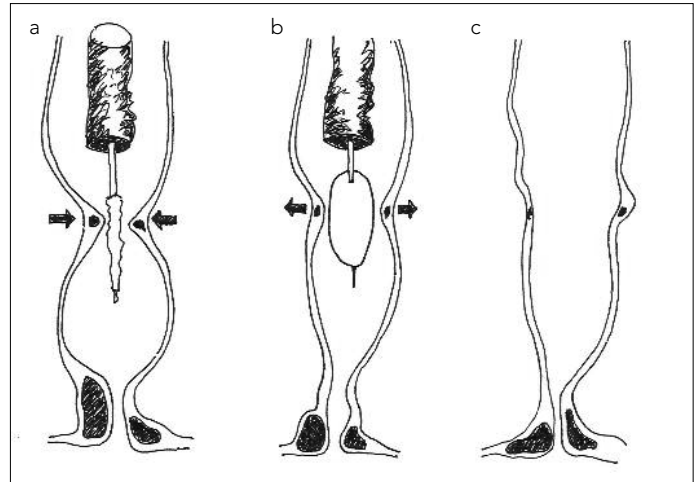
In the procedure performed with a guide wire, the wire is passed from the canal of the endoscope into the stomach (Picture 4). The guide wire is kept stable in its position and the endoscope is withdrawn. The bougie is advanced to the passage over the guide wire and the stricture is dilated. During dilatation with the Maloney bougie, the endoscopist acts by feeling and observing the findings.

Based on the preference and experience of endoscopists, dilatation can be performed only under fluoroscopy and by using or not using endoscopy with or without fluoroscopy. Some endoscopists routinely perform the procedure with the guidance of fluoroscopy and a wire in narrow strictures. Some endoscopists pass the guide wire through the stricture under the guidance of endoscopy without using fluoroscopy if the patient has undergone endoscopy previously or if the stomach can be seen from the distal of the stricture clearly. The contribution of fluoroscopy to dilatation is not obvious. In a study that included 83 patients with a benign stricture of the esophagus, Maloney bougies were used in the presence and absence of fluoroscopy (30). In patients whose procedures were performed with the guidance of fluoroscopy, the dysphagia scores were better (93% vs 69%) and the tolerance levels for swallowing 12.5 mm barium tablets were higher (62% vs 42%). In another study, it was specified that the experience of the endoscopist is more important than fluoroscopy (31).

- Through-the-scope (TTS) balloon dilators
- They pass through the biopsy canal of the endoscope and provide a direct view.
- They can provide 1–1.5 mm expansion in three planes without changing balloons.
- They are relatively expensive and single use only.
- Fluoroscopy is not necessary, but it can be needed in difficult cases.
- The results of comparisons with the Savary type are contradictory.

A study with 17 patients in each arm comparing balloon dilators with Savary dilators took involved more than 2 years study of patients and a diameter of 45F was targeted (32). While the rates of recurrence were similar in the first year, balloon dilatation gave better results in the second year. The relief of dysphagia was detected at similar rates with both techniques, but the balloon type was found to be superior in terms of dilatation comfort and the number of dilatations (1.1 ± 0.1 vs 1.7 ± 0.2).

In a prospective randomized study with 251 patients having a peptic esophageal stricture, no difference was found between



Picture 5. a-c. (a) Extension of a balloon dilator up to the stricture, (b) placing the balloon dilator on the stricture and inflating it, (c) esophageal lumen with passage (drawn by Dr. Doğan Gönüllü).

balloon and Savary dilators in terms of complications, immediate relief, and recurrent dysphagia.

TTS balloon dilatation

Many endoscopists take less education on balloon dilators than mechanical bougies. This may result from the fact that mechanical systems can be used more easily and safely compared to balloon dilators. On the other hand, prospective studies have demonstrated that balloon and mechanical systems give similar results in the dilatation of esophageal strictures. In addition, in another study, balloon dilators were found to be more advantageous with regard to the recurrence of strictures (29).

TTS balloon dilators are pushed beyond the stricture by passing through the process canal of the endoscope with the guidance of fluoroscopy with a direct view (Picture 5). During the inflation of the balloon, in order to prevent migration to the proximal end, the balloon sheath is held firmly and the endoscope is located just above the upper end of the balloon.

If the inflated balloon can easily be passed through the treated stricture until the proximal end, the dilatation process is considered to be successful. The maximum diameter must be ensured through fluoroscopic monitorization during the inflation of the balloon. For increasing visibility, the balloon should be filled with a water-soluble contrast agent in a 1/3 dilution. The proper dilatation is observed as a narrowing in the waist region of the balloon depending on the stricture's squeezing (33).

There is no evidence-based information on the time and number of balloon inflations. Most endoscopists inflate the balloon 2–3 times for 30–60 seconds in each session.

CHOICES ACCORDING TO THE CONDITION OF THE STRICTURE

Simple Strictures

They are mostly peptic strictures associated with prolonged reflux esophagitis and they are followed by a Schatzki ring (29). In most patients, the symptoms are healed with 1–3 dilatations, although more processes may be needed in 25–35% of patients

(6). They are the strictures through which an endoscope can be passed because they are smooth-surfaced, short, distally located, and generally larger than 1 cm. In these cases, safe and successful dilatations can be performed by using Maloney bougies (34). Some endoscopists prefer balloon dilators or a wire-guided bougie.

Complex strictures

The most common causes of complex strictures are caustic burn, radiotherapy, anastomosis, photodynamic therapy, and severe peptic damage (6). They are long, narrow, and tortuous strictures. They can coexist with large hiatal hernia, esophageal diverticula, or trachea-esophageal fistula and they require special dilatation systems and/or special attention and experience during application. Dilators cannot be passed into the stomach freely and there is a risk of esophageal perforation. For avoiding this risk, a wire-guided system or balloon dilators are used in complex strictures (32). In cases in which the wire cannot be advanced, especially in the proximal, it can be very difficult to obtain endoscopic success. In this situation, it may be required to reveal the stricture by retrogradely entering into the esophagus through a thin endoscope from the PEG tract, to use a soft or hard guide wire for passing the passage, or to pass the membrane by piercing with a needle-knife. This process can be performed with the help of rigid laryngoscope (32) or with a second flexible endoscope from the anterior aspect.

After providing a passage, dilatation is performed through wire-guided balloon dilators (retrograde) or Savary-Gillard dilators (antegrade). This type of radiation strictures may require repeating dilatations and keeping the lumen open by placing a nasogastric tube (25). For the relief of symptoms, at least three dilatations are necessary and the recurrence rate is high. If a complex stricture is not dilated enough for solid food to be swallowed, it recurs within 2–4 weeks, or if it requires dilatation sessions more than 7–10 times, it is considered to be a refractory stricture (6).

Sometimes, after passing through the stricture with a guide-wired system or balloon system at the beginning, dilator combinations, such as making dilatation with Maloney bougies, can be required. In upper esophageal strictures, procedures are performed with a wire-guided system (and if necessary, with fluoroscopy).

Alternatives in complex strictures: Electro-incision can be used in patients with a refractory or recurrent esophageal-gastric anastomosis stricture (6). Short, membranous, and hard strictures are more proper for this technique. A needle-knife used for ERCP is utilized for performing a radial incision in four quadrants in the stricture. Immediately after that, dilatation can be done with a 18–20 mm balloon dilator. Literature data show that this method is more effective and safer than other single dilatations.

The initial treatment in eosinophilic esophagitis is medical and surgery is considered when there is no response to initial treatment. Due to the risk of perforation, Savary or Maloney bougies are used very carefully. The relief of dysphagia is generally reached once a 13–14 mm passage is obtained and this criterion must be targeted. Mucosal rupture is a frequently seen complication and because it can often reach the muscular layer, it is necessary to investigate it through endoscopic control after dilata-

tion. In a literature review (18 studies), the relative perforation risk for 671 dilatations performed for 468 patients with eosinophilic esophagitis was found to be 0.1%, and it was thus suggested that the risk of this disease was exaggerated.

GENERAL RULES FOR ESOPHAGEAL DILATATION

Fasting before dilatation is important for a clear view of the lumen and for the prevention of aspiration (5). Moreover, anti-platelet and anti-coagulant drugs must be stopped 5 days before the process. Prophylactic antibiotics must be given to patients with a high risk of endocarditis (25).

Although Maloney bougies can be passed more easily while sitting, dilatation is generally performed in the left lateral decubitus position.

There is no study proving that fluoroscopy is necessary during dilatation and that it is safer. On the other hand, fluoroscopy can be beneficial especially during the application of a guide wire in blind passage in complicated strictures.

- The rule of three: This rule is applied only for wire-guided bougies, not for balloon dilators (7). The idea is to start with a bougie dilator that has approximately the same diameter as the lumen and to move with progressively larger dilators until feeling resistance to the passage of the dilator (for instance, starting with a 9-mm dilator and continuing with 10-, 11-, and 12-mm dilators). The dilator that causes resistance to passage is accepted as the first dilator, and then, second, and third dilators of sequential size are passed (totaling three dilators) (the physician should not skip a dilator size and should not skip from 10 mm to 14 mm). Sometimes, this rule is not followed depending on the experience of the endoscopist and the condition of the patient. On the other hand, in balloon dilatations for which this rule is not valid, it should not be begun with a 20-mm dilator. Instead, the endoscopist should cautiously prefer a 12-mm diameter balloon and increase the pressure in the following sessions.

The passage in a barium-tablet test performed for the success to be evaluated objectively is assessed by passing a 12.5-mm diameter barium tablet with 60 cc of water at an inclination of 45° in 20 seconds (15).

There is no consensus on the dilatation level that should be targeted in peptic esophageal strictures:

- An 18-mm (54F) diameter of the esophagus is sufficient for normal food intake unless there is a motility disorder. In patients with a lumen smaller than 13 mm (39F), the intake of solid food can lead to dysphagia. Some endoscopists accept a patient's inability to swallow 12-mm barium tablets as the objective triangulation point for the necessity of dilatation.
- The width of dilatation should be decided depending on the patient and considering the healing of symptoms and difficulties during treatment.
- Because most patients state their symptoms relieve with 40–50F dilatation, this level can be targeted.
- The initial dilatation should not be over 2 mm (6F) (35). In the same way, most endoscopists prefer 10, 11, and 12 mm

for balloon dilators sequentially. In order to prevent complications in narrow and long strictures, one or two dilatations should be preferred for each session.

- Experienced endoscopists can perform more aggressive dilatations in selected cases (36).
- If there is a resistance to dilatation in narrow strictures, the session must be repeated for 5 days in a week for the initial dilatation. After obtaining the first relief, frequency can be reduced.
- As a general rule, the largest diameter reached in the previous session is used as the first diameter in the next session. Despite this, it should be remembered that a stricture can narrow again and not every patient may tolerate the largest diameter in the previous dilatation. Because it is difficult to predict the extent of a recurring stricture, the diameter of the stricture should be re-evaluated before a new dilatation. Recurrent strictures may require a dilator with a smaller diameter. The experience of the patient in the previous session can also be useful for the selection of the dilator diameter.

To Ensure the Safety of Mucosal Biopsy Before Dilatation

Because taking a mucosal biopsy before dilatation theoretically has a risk for causing a large mucosal rupture during dilatation, biopsies are generally recommended to be taken after dilatation. This is not a fixed rule. It must be kept in mind that it may require re-swallowing the endoscope after dilatation, particularly in systems in which mechanical dilatation is used. There are few data on this point in literature, but it is understood that dilatation can be performed after endoscopic biopsy. In a small series (48 cases), dilatation was performed after biopsy without any complication (37).

Steroid Injection Into a Lesion

Steroid injection into a lesion is beneficial for a limited patient group. Although the action of mechanism is not exactly known, it is thought that steroids restrain the formation of collagen.


For avoiding the recurrence of dysphagia, a corticosteroid injection was performed and remarkable success has been achieved (38). In a randomized study, 15–18-mm balloon dilatations were successively applied in 30 patients with recurrent peptic strictures, and 0.5 cm triamcinolone (40 mg/cm³) was injected into four quadrants in addition to dilatation. In the study involving at least a one-year follow-up, while the rate of recurrence was 60% in patients undergoing only dilatation, this rate was 13% in patients who were additionally injected with a steroid (39). Similarly, a high level of success was obtained in the injection of 8 triamcinolone into the stricture and its proximal region in 71 patients (40).

In a randomized prospective study, 42 patients who underwent Savary dilatation by giving and not giving steroid into the lesion were examined. It was revealed that the need for re-dilatation in one year decreased in patients given a steroid (1.85 vs 5.5) (41). Further studies are needed for investigating this technique, the success of which can vary depending on the etiologies (6).

CONTRAINDICATIONS FOR DILATATION

The presence of a comorbid disease can elevate the risk of esophageal dilatation. Dilatation must be avoided or it must be performed very carefully in the following conditions (28):

1. Dilatation should be avoided in acute or unhealed esophageal perforations.
2. Dilatation should be postponed until the benign result of a biopsy is obtained in cases with suspicious malignancy.
3. In diseases with bleeding or in severe cardio-pulmonary diseases, whether endoscopy with or without dilatation will be tolerated by patient or not should be evaluated carefully.
4. Dilatation should be performed very carefully in the case of pharyngeal or cervical deformity, recent surgical or thoracic aneurysm, or impacted food.
5. Utmost attention should be paid in eosinophilic esophagitis for high perforation risk.



Picture 6. Esophageal stents: Left to right: Ultraflex, Z-stent, Polyflex, Niti-S, Choo and Bonastent

COMPLICATIONS OF DILATATION

During dilatation, the risk of perforation is 0.1–0.3% and the risk of bleeding is 0.2%. Moreover, bacteremia develops after dilatation in almost all patients, and cases developing brain abscess and bacterial endocarditis have been reported. The American Heart Association recommends antibiotic prophylaxis for patients with high risk. The selection of treatment method for a perforation suspect (7) depends on the location and diameter of the lesion and the time of diagnosis. Early diagnosis and immediate treatment are important for the prevention of mediastinal contamination from the site of leakage. Non-surgical treatment consists of endoscopic clipping in the place of perforation, insertion of a nasogastric tube, and application of an antibiotic. Completely coated, removable, and expandable stents can be inserted for closing perforations. Perforations in the very proximal can be closed only with a nasogastric tube in general. If there is secretion in the leakage, it can lead to infection. Contrast-enhanced radiographies (passage graphy and CT) can be helpful for deciding.

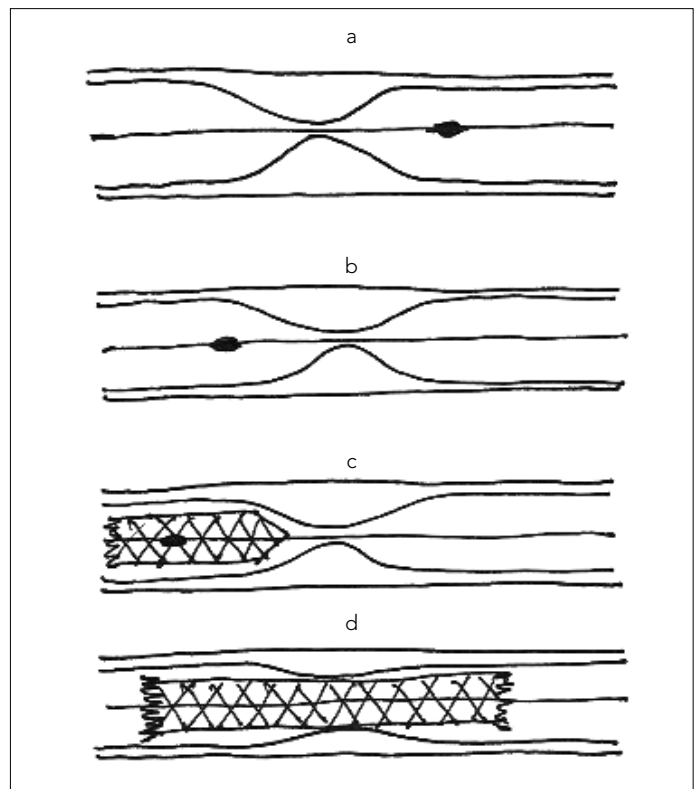
APPLICATION OF STENTS

Self-expandable Stents in Difficult Strictures

There is no self-expandable metal stent approved by FDA for the benign strictures of the esophagus (SEMS), but plastic stents are approved (Picture 6, Table 1) (7). These stents require great equipment. On the other hand, plastic stents that have less equipment and that can be easily applied have been developed. Non-coated SEMSs cannot be removed because they are embedded into the wall of the esophagus over time and they can cause long-term problems. On the other hand, completely coated metal stents are not embedded into the tissue. In autopsies, it has been demonstrated that the coating prevents the stent becoming embedded into the tissue. Although these stents have not been approved by the FDA, they can be used in refractory strictures, perforations, and postoperative leakages and can be removed when the time comes.

Stents that can provide palpation in malignant lesions are also used for refractory benign strictures. Non-coated self-expandable metal stents have serious complications. The most common complication is that the stent is embedded into the esophageal wall with the formation of granulation in the stent. This growth starts in 2–6 weeks after the insertion of the stent and causes the recurrence of stricture in 40% of patients (42).

For avoiding this situation, stents have been coated with silicon or polyester. There are three retrospective studies in which these stents were used (43). Successful results were reported in two studies. The symptoms were healed in 81% of patients in 21-month follow-up in the first study that included 21 patients (43) and in 80% of patients in 23-month follow-up in the second study with 15 patients (due to caustic burn, radiotherapy, anastomosis, and peptic). While no complication was reported in the first study, recurrent dysphagia in 5 patients (33%), hyperproliferation in 4 patients, and migration in 1 patient were observed in the second study that included 15 patients. In the third study, 84 stents were applied in 20 patients. Migration (62% patients), hyperplastic tissue growth (17% patients), and occurrence of stricture were found.



Picture 7. a-d. Application of a stent in an esophageal stricture: (a) First, a guide wire is passed beyond the stricture, (b) the olive-shaped tip is progressed at least 2 cm below the distal, (c) the outer sheath of the stent is pulled and slowly expanded, (d) the first part of the stent is completely extended and then the guide wire and others are removed (drawn by Dr. Doğan Gönüllü).

Table 1. The stents that are used and their features

	Ultraflex (Boston) USA	Z-stent (Wilson) USA	Polyflex (Boston) USA	NITI-S (TaeWoong) South Korea	Choo (M.I.Tech) South Korea	Bonastent (Standard) South Korea
Material	Nitinol	Steel	Polyester	Nitinol	Nitinol	Nitinol
Coating	Polyurethane	Polyurethane	Silicon	Polyurethane	Silicon	Silicon
Diameter, mm	18, 23	18	16, 18, 22, 21	16, 18	18	18
Internal diameter, mm	6	10	12, 14	6, 7	6	5
Length, cm	10–15	8–14	9–15	6–12	6–17	6–16

In hypopharyngeal located refractory strictures developing after radiation or surgery, stents with a normal diameter may not be satisfactory due to the feeling of a foreign body, severe pain, fistula, and perforation, and, sometimes, a feeding tube may be required. Cervical Niti-S stents can be used for not obligating the patient to a feeding tube and for allowing the patient to eat. The diameters of these stents are 10, 12, or 14 mm. Some have 2-mm larger parts at their distal ends, likened to "a dog bone," and they are coated. The risks for migration and recurrent stricture are high and they can require a new intervention in 6–12 weeks.

In hypopharyngeal resistant strictures, completely coated, 10–12 cm diameter and dog bone-shaped Niti-S stents can give better results. Most stents can be removed by pulling a plastic loop at the proximal loops. This process decreases the diameter of the stent and facilitates it being removed easily. For the stent to be removed with the guidance of fluoroscopy and the loop to be held, a hook was developed and 127 of 130 stents were removed with the success rate of 98%. While removing completely coated stents (Polyflex), a polyp snare or rat-toothed forceps can be used for holding the proximal end. Partially coated stents (Ultraflex) can be more easily removed by catching from their distal ends with rat-toothed forceps and invaginating (Picture 7).

Non-Metallic Stents

Increasing experience shows that non-metallic stents can be used in refractory strictures successfully (44). Silicon coated self-expanding plastic stents have been approved for benign strictures. SEPS must be left in its place for at least 6 weeks in order to allow the formation of scar tissue. In strictures developing radiation or anastomosis, longer time may be needed because of the increased risk of recurrence (29).

The largest series includes 40 cases with a benign stricture of the esophagus, which were applied a Polyflex stent for 4 weeks. The success rates of the insertion and removal of the stent were reported as 95% and 94%, respectively. The median dysphagia score was improved, but the rate of patients whose dysphagia disappeared was stated as 40% in the study with a one-year follow-up. Despite applying carefully selected patients, the complications of stent migration, severe chest pain, bleeding, perforation, gastroesophageal reflux, obstruction of the stent, and fistula were observed.

In a study that included 30 esophageal strictures, 83 stents were examined. Intervention was needed only in 6% of patients and stent migration was observed in 70–80% of patients according to localization.

In another study on 21 patients having benign strictures (peptic, caustic, post-radiotherapy, anastomosis, hyperplastic stricture developing after metal stent insertion) and being inserted a Polyflex stent, the stents were removed in terms varying from one week to 13 months (44). Early migration occurred in 5 patients and late migration was observed in 7 patients. The median duration of follow-up was 21 months. The insertion of the stent was specified as "curative" in 17 patients and their strictures were noted to be particularly associated with caustic burn and hyperplastic reason.

In a study that included the strictures of 11 patients who had undergone curative esophagectomy for esophageal tumors, it was

observed that dysphagia for solid food was relieved with the use of a stent in all the patients. Stent migration was detected in 7 patients and the time of repeating dilatation and/or re-stenting due to dysphagia was found to be 37 days (between 6 and 120 days) (45).

In a systematic review, 10 studies involving 130 patients were examined and it was revealed that SEPS stents were successfully inserted in 128 patients (98%), but no symptom developed only in 68 patients (52%) without the need for further endoscopic dilatation during 13-month follow-up. Stent migration occurred in 23% of patients in 4 weeks and endoscopic re-insertion was required in 21%. Moreover, 3 patients had perforation; 3 patients had bleeding, one of whom died; 2 patients developed tracheal compression and chest pain; stent could not be removed in 2 patients; and 1 patient had tracheal fistula.

Other Non-Metallic Stents

There are case reports on a biodegradable stent made of Poly-L-lactide (46). In a small series, SEPS was compared with a biodegradable stent made of polydioxanone. The first 20 patients with refractory benign esophageal strictures were applied SEPS and the other 16 patients were applied polydioxanone stent. No significant difference was found between the two groups in terms of the absence of dysphagia (30% vs 33%) or the occurrence of recurrent dysphagia (50% vs 67%) or major complications (10% vs 22%) during follow-up.

Metallic Stents

Non-coated expandable metal stents are not recommended to be used in benign strictures of the esophagus. They have a serious risk of complications ranging from stent trauma to fistulas. The most common complication is stenosis associated with fibrosis caused by stent in 40% of patients.

Fully coated, self-expandable metal stents (FCSEMS) were used in the benign strictures of the esophagus and were shown to be advantageous due to their being thin, flexible, and manipulable for insertion in the esophagus. Their being fully coated allows the stent to be removed easily. Four studies on the use of completely coated self-expandable stents in the benign strictures of the esophagus were evaluated (47). In one of the studies, the rate of refractory strictures was found to be 29% and the rate of migration was found to be approximately 1/3 in long-term follow-up (47). In other three studies, migration rates were reported to be between 34% and 39% and the success rates of treatment were stated to be between 21% and 100% (48).

For preventing migration, FCSEMS stents, the ends of which are partially expanded (flare) and designed in the shape of a "dog bone," are used. In a series of 31 patients, these stents were used (due to fistula or leakage in 15 patients, refractory benign stricture in 9 patients, anastomotic stricture in 4 patients, and radiation stricture in 3 patients). The dysphagia score or fistula/leakage was improved in 90% of patients and stent migration occurred in 26% of patients (all on the first day). It was specified that the partially low migration might be attributed to the design in the shape of a dog bone. All the stents were removed using an endoscopic technique. In one patient, a second internal stent was inserted in the second session and all the stents were

removed in the third session. In another patient, the stent was removed during fistula surgery.

Results of Patients Being Inserted a Stent

In the study of Bakken et al. (48), all stents were removed without any difficulty (although some were kept for a long time), but the migration rate was found to be high (35.6%). Because migrations were generally toward the stomach, no serious complications developed. However, after the removal of stents, the rate of recurrence was above 50% (48). On the other hand, the success rate in fistulas and perforations was 38% (7).

Complications of Stents

The likelihood of developing complications is high in the use of self-expandable fully coated plastic and metal stents. Some airway problems, such as compression and aspiration, and sedation-related complications can develop during the insertion of stents. Temporary pain, nausea, and vomiting are not rare. Stent migration associated with the coating material that is used for preventing the stent becoming embedded in the tissue is usual. Although not common, after healing the original stricture, new strictures may occur at the points where the ends of stent are located, but it has not been explained yet whether these new strictures develop due to a patient's susceptibility or not. In some patients, granulation tissue that may develop around the stent due to stent irritation can be dissolved after the stent is removed. Bleeding and tracheo-esophageal fistulas secondary to ulcers associated with stent irritation have been reported (7).

OTHER TECHNIQUES

Mitomycin-C injection: This was successfully applied in a very refractory proximal stricture of the esophagus, which developed due to radiotherapy given after thyroid cancer (29).

Endoscopic stricturoplasty (Incision treatment): In two case series, in which incision was performed on four quadrants using a thin blade under the guidance of a Savary dilators, success was achieved in eight of eight patients (29) and in five of six patients, respectively.

In some cases, the endoscopic electrocautery incision technique was applied in benign refractory strictures of the esophagus (peptic, postoperative, and Schatzki) (49). However, the safety of this technique is unclear.

Tissue ischemia generally develops due to anastomosis leakage and radiotherapy. As an alternative to repeated dilatations, incision treatment was performed with electrocautery or endoscopic scissors and argon plasma coagulation. In the series in which only electrocautery was used, after doing dilatation for three times in 20 patients with a refractory anastomosis stricture, an incision through which the endoscope could easily pass was performed. The stricture was shorter than 1 cm in 12 patients (60%) and dysphagia was healed after a single process. In another 8 patients (40%) with strictures in the lengths of 1.5–5 cm, approximately three electrocautery sessions were required for healing the symptoms. Complications involving perforation or bleeding were not observed. In patients with a recurrent Schatzki ring, the technique was applied successfully in approximately three sessions.

Pharyngo-esophageal puncture: This has been defined for patients with a complete or severe level of strictures stenosis (50). It consists of the combination of a guide wire, endoscopic balloon, and puncturing tool, and it was developed based on the ERCP technique. It was successfully applied in three cases.

SURGICAL TREATMENT

When should patients be directed to surgery?

Surgery, which has a serious morbidity and mortality risk due to technical difficulties, should be considered as the final choice in most patients. It will require opening of the thorax or the abdomen depending on the location of the stricture. Refractory strictures are generally localized at the distal end and can be resected more easily. In refractory strictures in the middle esophagus and especially at the proximal, surgery is difficult and it can also affect the airway (7).

The application of surgical treatment in peptic esophageal strictures is still controversial. In patients who do not respond to aggressive medical treatment or who cannot be given medical treatment, surgical treatment can be indicated. The occurrence of recurrence despite PPI drug treatment is rare.

Various procedures have been defined and these are increasingly applied laparoscopically (5):

- Preventive procedures for the esophagus: Standard anti-reflux surgery (Nissen total or Belsey-Mark IV partial fundoplication) or surgeries for the extension of the esophagus in addition to anti-reflux surgery (Collis-Nissen or Belsey gastropasty) (5).
- Esophageal resection and reconstruction: Stomach or colon or jejunal segment interposition; standard anti-reflux surgery and postoperative dilatation can be recommended if the esophagus is in normal length. If the esophagus is short, Collis gastropasty and postoperative dilatation can be recommended. If the stricture cannot be dilated, esophageal resection and interposition is recommended (5).

PATIENT FOLLOW-UP

- The necessities of medication, dilatation, or surgery for a patient's reflux and dysphagia should be decided on after a close follow-up.
- For recurrent dysphagia or atypical reflux symptoms, dilatation can be repeated, and in case of failure, surgery can be planned.
- Patients should be warned about obeying recommendations on diet and lifestyle.
- It is very important to use PPI drugs, which have been shown to prevent recurrence of peptic esophageal strictures and to decrease the number of dilatations, for a long time. The dose of PPI drugs should be determined according to the response of patients and endoscopy findings. The need for high doses of PPI drugs for reaching a satisfying result is not unusual.
- Patients must be warned about drugs that can lead to esophagitis, such as aspirin and NSAIDs (5).

PROGNOSIS

Patients should be warned that an esophageal stricture can develop and that the stricture can recur if the use of PPI drugs is neglected. The absence of retrosternal heartburn and significant weight loss among initial findings can show poor prognosis. The weight, type, and diameter of the initial stenosis do not affect the recurrence of stricture.

In many studies, it was revealed that the progressive application of dilatation up to a diameter of 40–60F in peptic strictures relieved dysphagia in 85% of patients with a low complication rate. On the other hand, dilatation was repeated in approximately 30% of patients within a year and this rate was found to be 60% in those not receiving anti-secretory drug supports.

The success rate of surgical procedure varies between 43% and 90%, depending on the surgeon's experience and the health center's patient capacity with esophageal stricture, but it is generally around 77%.

The need for dilatation after surgery occurs in 1–43% of patients and 1–2 sessions are generally required. Mortality rates are below 0.5% and morbidity rates are below 20%. There are no well-controlled studies showing the safety, efficiency, and results of surgical procedures including dilatation when necessary and PPI drugs (5).

Peer-review: Externally peer-reviewed.

Author Contributions: Concept - F.N.K.; Design - F.N.K., D.G.; Supervision - D.G.; Resource - F.N.K., D.G.; Materials - F.N.K.; Data Collection and/or Processing - F.N.K.; Analysis and/or Interpretation -F.N.K., D.G.; Literature Review - F.N.K., D.G.; Writer - F.N.K.; Critical Review - D.G.; Other - D.G.

Conflict of Interest: No conflict of interest was declared by the authors.

Financial Disclosure: The authors declared that this study has received no financial support.

REFERENCES

- Kelly HD. Origins of oesophagology. *Proc R Soc Med* 1969; 62: 781-6.
- Hildreth CH. Stricture of the esophagus. *N Engl J Med Surg* 1821; 10: 235.
- Goyal RK, Bauer JL, Spiro HM. The nature and location of lower esophageal ring. *N Engl J Med* 1971; 284: 1175-80. (CrossRef)
- Lewis MI, McKenna RJ (eds). *Medical Management of the Thoracic Surgery Patients*. Soukiasian HJ, Luketich JD. Benign Esophageal Disease, Saunders-Elsevier, Philadelphia, Chapter 57, 2010.
- Mukherjee S, Katz J. Esophageal stricture, Jan 4 2012, Available from: <http://emedicine.medscape.com/article/175098-overview>
- Siersema PD. Treatment options of esophageal strictures. *Nat Clin Pract Gastroenterol Hepatol* 2008; 5: 142-52. (CrossRef)
- Baron TH. Management of Benign Esophageal Strictures. *Gastroenterol Hepatol (N Y)* 2011; 7: 46-9.
- Pines G, Klein Y, Melzer E, Idelevich E, Buyeviz V, Machlenkin S, et al. One hundred transhiatal esophagectomies: a single-institution experience. *Isr Med Assoc J* 2011; 13: 428-33.
- Yendamuri S, Gutierrez L, Oni A, Mashtare T, Khushalani N, Yang G, et al. Does circular stapled esophagogastric anastomotic size affect the incidence of postoperative strictures? *J Surg Res* 2011; 165: 1-4. (CrossRef)
- Lawson JD, Otto K, Grist W, Johnstone PA. Frequency of esophageal stenosis after simultaneous modulated accelerated radiation therapy and chemotherapy for head and neck cancer. *Am J Otolaryngol* 2008; 29: 13-9. (CrossRef)
- Umsawasdi T, Valdivieso M, Barkley HT Jr, Booser DJ, Chiuten DF, Murphy WK, et al. Esophageal complications from combined chemotherapy (cyclophosphamide + adriamycin + cisplatin + xrt) in the treatment of non-small cell lung cancer. *Int J Radiat Oncol Biol Phys* 1985; 11: 511-9. (CrossRef)
- Wang KK, Lutzke L, Borkenhagen L, Westra W, Song MW, Prasad G, et al. Photodynamic therapy for Barrett's esophagus: does light still have a role? *Endoscopy* 2008; 40: 1021-5. (CrossRef)
- Wijburg FA, Heymans HS, Urbanus NA. Caustic Esophageal lesions in childhood: Prevention of stricture formation. *J Pediatr Surg* 1989; 24: 171-3. (CrossRef)
- Coln D, Chang JH. Experience with esophageal stenting for caustic burns in children. *J Pediatr Surg* 1986; 21: 588-91. (CrossRef)
- Bulut T. Selim özofagus striktürleri, Available from: <http://www.oocities.org/turkerbulut/trSelim.html>
- Ono S, Fujishiro M, Niimi K, Goto O, Kodashima S, Yamamichi N, et al. Predictors of postoperative stricture after esophageal endoscopic submucosal dissection for superficial squamous cell neoplasms. *Endoscopy* 2009; 41: 661-5. (CrossRef)
- Valentine R, Gangloff J, MacGillivray D. Supraclavicular approach for the simultaneous treatment of dysphagia lusoria and thoracic outlet syndrome. *Ann Vasc Surg* 1988; 2: 378-80. (CrossRef)
- Pace F, Antinori S, Repici A. What is new in esophageal injury (infection, drug-induced, caustic, stricture, perforation)? *Curr Opin Gastroenterol* 2009; 25: 372-9. (CrossRef)
- Dolar ME, Boyacioglu AS, Ates KB, Caner ME, Hilmioğlu F, Sahin B. Esophageal strictures after endoscopic injection sclerotherapy. *Endoscopy* 1994; 26: 370. (CrossRef)
- Ahtaridis G, Snape WJ, Cohen S. Clinical and manometric findings in benign peptic strictures of the esophagus. *Dig Dis Sci* 1979; 24: 858-61. (CrossRef)
- Swarbrick ET, Gough AL, Foster CS. Prevention of recurrence of oesophageal stricture, a comparison of lansoprazole and high-dose ranitidine. *Eur J Gastroenterol Hepatol* 1996; 8: 431-8.
- McLean GK, LeVein RF. Shear stress in the performance of esophageal dilation: comparison of balloon dilation and bougienage. *Radiology* 1989; 172: 983. (CrossRef)
- Dakkak M, Hoare RC, Maslin SC. Oesophagitis is as important as oesophageal stricture diameter in determining dysphagia. *Gut* 1993; 34: 152-5. (CrossRef)
- Smith PM, Kerr GD, Cockel R. A comparison of omeprazole and ranitidine in the prevention of recurrence of benign esophageal stricture. Restore Investigator Group. *Gastroenterology* 1994; 107: 1312-8. (CrossRef)
- Silvis SE, Farahmand M, Johnson JA. A randomized blinded comparison of omeprazole and ranitidine in the treatment of chronic esophageal stricture secondary to acid peptic esophagitis. *Gastrointest Endosc* 1996; 43: 216-21. (CrossRef)
- Marks RD, Richter JE, Rizzo J. Omeprazole versus H2-receptor antagonists in treating patients with peptic stricture and esophagitis. *Gastroenterology* 1994; 106: 907-15. (CrossRef)
- Moayyedi P, Leontiadis GI. The risks of PPI therapy. *Nat Rev Gastroenterol Hepatol* 2012; 9: 132-9. (CrossRef)
- Jones MP, Bratten JR, McClave SA. The Optical Dilator: a clear, over-the-scope bougie with sequential dilating segments. *Gastrointest Endosc* 2006; 63: 840-5. (CrossRef)
- Guelrud M, Saltzman JR, Travis AC. Management of benign esophageal strictures. UpToDate, 24 Agus 2011, Available from: <http://www.uptodate.com/contents/management-of-benign-esophageal-strictures>

30. Kozarek RA, Patterson DJ, Ball TJ, Gelfand MG, Jiranek GE, Bredfeldt JE, et al. Esophageal dilation can be done safely using selective fluoroscopy and single dilating sessions. *J Clin Gastroenterol* 1995; 20: 184-9. [\(CrossRef\)](#)
31. Ho SB, Cass O, Katsman RJ, Lipschultz EM, Metzger RJ, Onstad GR, et al. Fluoroscopy is not necessary for Maloney dilation of chronic esophageal strictures. *Gastrointest Endosc* 1995; 41: 11-4. [\(CrossRef\)](#)
32. Bueno R, Swanso SJ, Jaklitsch MT, Lukanich JM, Mentzer SJ, Sugarbaker DJ. Combined antegrade and retrograde dilation: A new endoscopic technique in the management of complex esophageal obstruction. *Gastrointest Endosc* 2001; 54: 368-72. [\(CrossRef\)](#)
33. Kozarek RA. To stretch or to shear: a perspective on balloon dilators. *Gastrointest Endosc* 1987; 33: 459-61. [\(CrossRef\)](#)
34. Wesdorp IC, Bartelsman JF, den Hartog Jager FC, Huibregtse K, Tytgat GN. Results of conservative treatment of benign esophageal strictures: a follow-up study in 100 patients. *Gastroenterology* 1982; 82: 487-93.
35. Tulman AB, Boyce HW Jr. Complications of esophageal dilation and guidelines for their prevention. *Gastrointest Endosc* 1981; 27: 229-34. [\(CrossRef\)](#)
36. Bakken JC, Wong Kee Song LM, de Groen PC, Baron TH. Use of a fully covered self-expandable metal stent for the treatment of benign esophageal diseases. *Gastrointest Endosc* 2010; 72: 712-20. [\(CrossRef\)](#)
37. Barkin JS, Taub S, Rogers AI. The safety of combined endoscopy, biopsy and dilation in esophageal strictures. *Am J Gastroenterol* 1981; 76: 23-6.
38. Zein NN, Greseth JM, Perrault J. Endoscopic intralesional steroid injections in the management of refractory esophageal strictures. *Gastrointest Endosc* 1995; 41: 596-8. [\(CrossRef\)](#)
39. Ramage JI Jr, Rumalla A, Baron TH, Pochron NL, Zinsmeister AR, Murray JA, et al. A prospective, randomized, double-blind, placebo-controlled trial of endoscopic steroid injection therapy for recalcitrant esophageal peptic strictures. *Am J Gastroenterol* 2005; 100: 2419-25. [\(CrossRef\)](#)
40. Kochhar R, Makharia GK. Usefulness of intralesional triamcinolone in treatment of benign esophageal strictures. *Gastrointest Endosc* 2002; 56: 829-34. [\(CrossRef\)](#)
41. Dunne DP, Rupp T, Rex DK, Lehman GA. Five year follow-up of prospective randomized trial of Savary dilation with or without intra-lesional steroids for benign gastroesophageal reflux strictures. *Gastroenterology* 1999; 116: 152.
42. Cwikiel W, Willen R, Stridbeck H, Lillo-Gil R, von Holstein CS. Self-expanding stent in the treatment of benign esophageal strictures: Experimental study in pigs and presentation of clinical cases. *Radiology* 1993; 187: 667-71. [\(CrossRef\)](#)
43. Evrard S, Le Moine O, Lazaraki G, Dormann A, El Nakadi I, Devière J. Self-expanding plastic stents for benign esophageal lesions. *Gastrointest Endosc* 2004; 60: 894-900. [\(CrossRef\)](#)
44. Song HY, Jung HY, Park SI, Kim SB, Lee DH, Kang SG, et al. Covered retrievable expandable nitinol stents in patients with benign esophageal strictures: initial experience. *Radiology* 2000; 217: 551-7. [\(CrossRef\)](#)
45. Oh YS, Kochman ML, Ahmad NA, Ginsberg GG. Clinical outcomes after self-expanding plastic stent placement for refractory benign esophageal strictures. *Dig Dis Sci* 2010; 55: 1344-8. [\(CrossRef\)](#)
46. Fry SW, Fleischer DE. Management of a refractory benign esophageal stricture with a new biodegradable stent. *Gastrointest Endosc* 1997; 45: 179-82. [\(CrossRef\)](#)
47. Eloubeidi MA, Lopes TL. Novel removable internally fully covered self-expanding metal esophageal stent: feasibility, technique of removal, and tissue response in humans. *Am J Gastroenterol* 2009; 104: 1374-81. [\(CrossRef\)](#)
48. Bakken JC, Wong Kee Song LM, de Groen PC, Baron TH. Use of a fully covered self-expandable metal stent for the treatment of benign esophageal diseases. *Gastrointest Endosc* 2010; 72: 712-20. [\(CrossRef\)](#)
49. Thorsen G, Rosseland AR. Endoscopic incision of postoperative stenoses in the upper gastrointestinal tract. *Gastrointest Endosc* 1983; 29: 26-9. [\(CrossRef\)](#)
50. Tang SJ, Singh S, Truelson JM. Endotherapy for severe and complete pharyngo-esophageal post-radiation stenosis using wires, balloons and pharyngo-esophageal puncture (PEP) (with videos). *Surg Endosc* 2010; 24: 210-4. [\(CrossRef\)](#)