

Pathogenetic and Prognostic Importance of Cyclin D1, Estrogen Receptor, and TAG72 in Cutaneous Vascular Tumors and Pericytic Tumors

Kutanöz Vasküler Tümörlerde ve Perisitik Tümörlerde Cyclin D1, Östrojen Reseptörü ve TAG72'nin Patogenetik ve Prognostik Önemi

Sevil Karabağ¹, Kıvılcım Erdoğan², Akif Mirioğlu³, Özge Zorlu⁴, Gülfiliz Gönülşen², Serdar Özbarlas³

¹Tekirdağ Namık Kemal University Faculty of Medicine, Department of Pathology, Tekirdağ, Turkey

²Çukurova University Faculty of Medicine, Department of Pathology, Adana, Turkey

³Çukurova University Faculty of Medicine, Department of Orthopedics and Traumatology, Adana, Turkey

⁴Tekirdağ Namık Kemal University Faculty of Medicine, Department of Dermatology and Venereology, Tekirdağ, Turkey

Cite this article as: Karabağ S, Erdoğan K, Mirioğlu A, Zorlu Ö, Gönülşen G, Özbarlas S. Pathogenetic and Prognostic Importance of Cyclin D1, Estrogen Receptor, and TAG72 in Cutaneous Vascular Tumors. J Acad Res Med 2022;12(3):137-42

ABSTRACT

Objective: The present study aims to investigate the presence of pericyte loss in malignant vascular tumors and investigate the expression of cell cycle regulators, cyclin D1 and estrogen receptor (ER), and tumor-associated glycoprotein 72 (TAG72) in tumor cells and tumor microenvironment in benign/malignant vascular tumors and benign/malignant pericytic tumors.

Methods: Cyclin D1, ER, and TAG72 were examined by immunohistochemistry in 38 cases of tumors of vascular and pericytic origins. The data on metastasis and prognosis of malignant cases were retrieved from the hospital information system.

Results: The 38 patients included the following types of neoplasms: hemangioma (n=16), glomus tumor (n=9), epithelioid angiosarcoma (n=8), epithelioid hemangioendothelioma (n=3), infantile hemangiopericytoma (n=1), and malignant glomus tumor (n=1). No statistically significant difference was found in cyclin D1 expression between pericyte-derived tumors and malignant vascular tumors (p=0.508). When benign-malignant vascular and pericytic tumors were compared, no statistically significant difference was found in cyclin D1 expression between the 4 groups (p=0.465). No statistically significant difference was observed in staining between tumors of vascular and pericytic origin (p=0.104). ER expression was detected in only one case of malignant glomus tumor. TAG72 expression was not observed in any of the cases.

Conclusion: The present study supports the notion that cyclin D1 may be present as a driver mutation in this group of tumors. The findings of this study did not produce any data to support the hypothesis claiming that pericyte loss led to malignancy. We believe that our results on the comparison of cell cycle protein expressions in cutaneous vascular and pericytic tumors shed light for future studies to elucidate the pathogenesis of this group of rare tumors.

Keywords: Vascular tumor, pericyte, cyclin D1, estrogen receptor, TAG72

ÖZ

Amaç: Malign vasküler tümörlerde perisit kaybının varlığını araştırmak, ayrıca vasküler ve perisitik kökenli tümörlerde, tümör hücreleri ile tümör mikroçevresinde hücre döngüsü düzenleyicileri siklin D1, östrojen reseptörü (ER) ve tümör ilişkili glikoproteini 72 (TAG72) ekspresyonlarının varlığını saptamak amaçlanmıştır.

Yöntemler: Toplam 38 vasküler ve perisitik kökenli tümörde immünohistokimya ile siklin D1, ER ve TAG72 çalışıldı. Malign olguların metastaz ve prognoz verileri hastane bilgi sisteminden kaydedildi.

ORCID IDs of the authors: S.K. 0000-0002-8855-3798; K.E. 0000-0002-4951-8703; A.M. 0000-0002-9686-4991; Ö.Z. 0000-0001-5555-130X; G.G. 0000-0003-3065-1683; S.Ö. 0000-0001-7950-1438.

Corresponding Author/Sorumlu Yazar: Sevil Karabağ,

E-mail: eesevil-krbg@hotmail.com

Received Date/Geliş Tarihi: 13.08.2022 **Accepted Date/Kabul Tarihi:** 23.11.2022

©Copyright 2022 by University of Health Sciences Turkey, Gaziosmanpaşa Training and Research Hospital. Available on-line at www.jarem.org

©Telif Hakkı: 2022 Sağlık Bilimleri Üniversitesi, Gaziosmanpaşa Eğitim ve Araştırma Hastanesi. Makale metnine www.jarem.org web sayfasından ulaşılabilir.



Bulgular: Otuz sekiz hastamızda tespit edilen tümörlerin dağılımı şu şekilde idi: 16 hemanjiyom, 9 glomus tümörü, 8 epithelioid anjiyosarkom, 3 epitelioid hemanjiyoendotelyoma, 1 infantil hemangioperisitom ve 1 malign glomus tümörü. Perisit kökenli tümörler ile malign vasküler tümörlerin siklin D1 ekspresyonları arasında istatistiksel anlamlı fark saptanmadı ($p=0,508$). Benign-malign vasküler-perisitik tümörler kıyaslandığında dört grup arasında siklin D1 ekspresyonunda istatistiksel anlamlı fark saptanmadı ($p=0,465$). Vasküler ve perisitik kökenli tümörler arasında da istatistiksel anlamlı boyanma farkı saptanmadı ($p=0,104$). Yalnızca bir malign glomus tümürlü olguda ER ekspresyonu izlendi. Hiçbir olguda TAG72 ekspresyonu gözlenmedi.

Sonuç: Çalışmamız siklin D1'in bu grup tümörlerde driver mutasyon olarak bulunabileceğini desteklemektedir. Perisit kaybının maligniteye yol açtığı hipotezini destekleyecek veri elde edilememiştir. Oldukça nadir görülen bir grup tümör olan kutanöz vasküler ve perisitik kökenli tümörlerin hücre siklus protein ekspresyonlarını kıyaslayarak bu grup tümörlerin patogenezi aydınlatacak çalışmalara ışık tuttuğumuzu düşünmekteyiz.

Anahtar kelimeler: Vasküler tümör, perisit, siklin D1, östrojen reseptörü, TAG72

INTRODUCTION

Vascular tumors are endothelium-derived neoplasms that are categorized as benign, intermediate, or malignant based on the World Health Organization classification of soft tissue tumors. The most common type of these tumors is hemangiomas, where total excision results in cure. However, recurrence may occur in patients in whom total excision cannot be performed, such as vertebral hemangiomas. The differential diagnosis of benign vascular tumors from malignant tumors is of critical importance and may sometimes be challenging, as is the case with anastomosing or epithelioid hemangiomas. The intermediate group involves retiform hemangioendothelioma, papillary intralymphatic angioendothelioma, composite hemangioendothelioma, Kaposi's sarcoma and pseudomyogenic hemangioendothelioma, which are locally aggressive tumors that rarely metastasize. Epithelioid hemangioendothelioma and angiosarcoma are malignant vascular tumors. Glomus tumor is the most common type of pericyte-derived tumors, and only a limited number of patients with malignant glomus tumor has been reported in the literature to date (1,2).

Accumulating observations show that not only genetic abnormalities in malignant cells but also tumor microenvironment play an effective role in the physiopathology of cancer. In addition to cancer-associated fibroblasts, immune cells, endothelial cells and pericytes are also the main cellular components of tumor microenvironment, and their various functions in tumor initiation and progression have been the subject of recent researches (3).

The first stage of tumor angiogenesis begins with pericyte-endothelial cell detachment. The detachment of pericytes, which are responsible for vascular stabilization, from the vascular wall allows endothelial cells to migrate to the surrounding matrix to form new blood vessels while increased vascular permeability leads to leakage of plasma proteins, which serve as a temporary matrix for the endothelium, as well as pericyte migration between integrins and plasma proteins (4,5). The facts that pericytes are the main cells that initiate tumor angiogenesis and that the way pericytic cell loss impairs vascular stabilization have led us to the question, "Do vascular tumors become malignant in the event of pericytic cell loss?"

The effects of estrogen and estrogen receptors (ER) on the G1 and G1-S phases of the cell cycle are well-established. Central to these cell cycle checkpoint mechanisms are the retinoblastoma susceptibility gene, pRB and the cyclin D1-CDK4 and cyclin E-CDK2 complexes that phosphorylate substrates, thereby allowing the initiation of DNA synthesis (6).

The present study aims to investigate the presence of pericyte loss in malignant vascular tumors and investigate the expression of cell cycle regulators, cyclin D1 and ER, and tumor-associated glycoprotein 72 (TAG72) in tumor cells and tumor microenvironment in benign/malignant vascular tumors and benign/malignant pericytic tumors in order to elucidate the pathogenesis of vascular and pericyte-derived tumors.

METHODS

Cutaneous vascular tumors and pericytic tumors diagnosed at pathology departments of two tertiary centers between 2016-2020 were included in the study. Data on the diagnosis, age, tumor location, metastasis and prognosis of the patients were retrieved from the hospital information system. This was a retrospective study of the archived materials of these patients.

Immunohistochemistry

Sections of 4-micron thickness were obtained from 38 paraffin-embedded archive tissues for immunohistochemistry (IHC) analysis, and then, these sections were deparaffinized and placed in a BenchMark XT device. Staining was performed after applying the antibodies, cyclin D1 (Ventana, RTU, clone SP4-R, USA), ER (Ventana, RTU, clone SP1, USA) and TAG72 (Cell Marque, RTU clone B72.3, USA). The preparations stained in an automated staining device were covered using an appropriate fluid-based covering material. Results were evaluated with an Olympus BX51 microscope.

Immunohistochemistry Evaluation

Scoring was performed simultaneously by two independent pathologists blinded for the clinical data. The intensity of cyclin D1 IHC staining was scored as +1, +2, and +3 for weak, moderate, and strong stains, respectively. The IHC score of cyclin D1 was reported as negative, low score (+1) and high score (+2 & +3) (7). ER expression was quantified in line with the scoring system

proposed by Remmele and Stegner (8) for ER in breast cancer. Staining intensity was scored from 0 (no reaction) to 3 (strong reaction), and the percentage of stained nuclei was scored from 0 (no positive nuclei) to 4 (more than 80% positive nuclei). The scores of staining intensity and stained nuclei were then multiplied, yielding a total score of 0 to 12. Positive ER expression was defined as a score of 3 or more (9).

For the IHC evaluation of TAG72, we used the 12-point Remmele scoring system (score: 0-12). To calculate this score, a number out of 0, 1, 2, or 3 was chosen according to the intensity of staining, and a number out of 0, 1, 2, 3, or 4 was chosen according to the percentage of positive tumor cells. The final scores of staining intensity and stained nuclei were then multiplied, yielding a total score of 0 to 12(3×4). In this study, total scores below 3 were considered negative, and scores of 4-12 were considered positive (8,10).

Statistical Analysis

Patient demographics and data were analyzed using the SPSS 24 (IBM Corp., Armonk, NY, USA) software. The chi-square test was used to compare variables between the patients in groups, and the Kruskal-Wallis test was used for comparisons across the 4 groups. $P < 0.05$ was considered statistically significant.

The study was approved by the Çukurova University Faculty of Medicine Non-Interventional Clinical Trials Ethics Committee (number: 102, date: 7 august 2020).

RESULTS

Of the 38 patients, 26 had benign (16 hemangiomas, 9 glomus tumors, 1 infantile hemangiopericytoma) and 12 had malignant (8 epithelioid angiosarcomas, 3 epithelioid hemangioendotheliomas, 1 malignant glomus tumor) tumors. The tumors were in the extremities or the head and neck regions. The mean age of the 38 patients was 41.9 years (minimum: 1, maximum: 78).

The distribution of cyclin D1 and ER staining in tumor cells and ER staining in tumor microenvironment by diagnosis are shown in Table 1. There was no TAG72 staining in tumor cells and/or tumor microenvironment in any of the patients. No cyclin D1 staining was observed in tumor microenvironment in any of the patients.

Comparison of cyclin D1 expression between pericyte-derived tumors (9 glomus tumors, 1 infantile hemangiopericytoma, 1 malignant glomus tumor) and malignant vascular tumors (8 epithelioid angiosarcomas, 3 epithelioid hemangioendotheliomas) did not reveal a statistically significant difference ($p=0.508$). The cyclin D1, ER and TAG72 immunostainings in a malignant glomus tumor are presented in Figure 1.

Cyclin D1 and ER staining, follow-up duration, and metastasis status of malignant tumors are presented in Table 2.

When benign and malignant vascular and pericytic tumors were compared, no statistically significant difference was found in terms of cyclin D1 expression between the four groups ($p=0.465$). No statistically significant difference was observed in terms of cyclin D1 staining between vascular tumors and tumors of pericytic origin ($p=0.104$). Table 3 shows the cyclin D1 expression of the patients by diagnosis. Cyclin D1 immunostainings of the patients with hemangioma, hemangioendothelioma, and angiosarcoma are presented in Figure 2.

DISCUSSION

A better understanding of the variable expression of different pericyte markers in tumors would provide a better understanding of pericyte-mediated angiogenesis. Since there are only a limited number of studies in the literature, especially in tumors such as angiosarcoma, epithelioid hemangioendothelioma and malignant glomus tumor, which are rare and have poor prognosis, we believe that there is a need for studies aiming to elucidate the pathogenesis and shed light for further research on the treatment of these tumors. Although conducted with relatively small sample size, the present study is one of the few studies in the literature investigating the expression of cell cycle-regulatory proteins such as cyclin D1, ER, and TAG72 in tumors of vascular and pericytic origins to shed light on the pathogenesis of this group of tumors. We detected cyclin D1 expression in both benign and malignant tumors of vascular and pericytic origins, and we observed ER expression only in one case of malignant glomus tumor. We did not find a significant difference in these proteins between pericyte-derived tumors and vascular tumors. Our results suggest

Table 1. Distribution of cyclin D1 and ER staining in tumor cells and tumor microenvironment by diagnosis

Diagnosis	Cyclin D1			ER in tumor cells		ER in tumor microenvironment		Total number of cases
	Neg	Low score	High score	Negative	Positive	Negative	Positive	
Hemangioma	3	3	10	16	0	16	0	16
Glomus	1	2	6	9	0	9	0	9
Infantile hemangiopericytoma	0	1	0	1	0	1	0	1
Epithelioid hemangioendothelioma	1	1	1	3	0	3	0	3
Angiosarcoma	0	5	3	8	0	8	0	8
Malignant glomus	0	1	0	0	1	0	1	1

ER: estrogen receptor

that especially cyclin D1 may be present as a driver mutation in this group of tumors; however, further comprehensive research is needed on this subject matter. Furthermore, we did not detect pericyte loss in malignant tumors. Findings of this study did not produce any data to support the hypothesis claiming that pericyte loss led to malignancy.

Overexpression of cyclin D1 may serve as a driver oncogene through the cell cycle-regulatory function of this protein. In the literature, amplification and/or overexpression of cyclin D1 has been shown in various human tumors, such as breast and parathyroid neoplasms (11). Moreover, there are studies supporting that this parameter indicates poor prognosis in tumors such as endometrial tumors (7). In our study, we found no significant difference in cyclin D1 expression between benign and malignant tumors. We detected low or high scores of cyclin D1 expression in 11 of our 12 malignant tumors. Despite the small sample size and limited follow-up period in our study, we believe that cyclin D1 expression may be a prognostic factor to predict metastasis and life expectancy in angiosarcoma cases provided that this is confirmed in larger future studies. Girard et al. (12) detected cyclin D1 expression in 12 of 16 benign glomus tumors located in the upper digestive tract and suggested that cyclin D1 overexpression might be involved in the pathogenesis of glomus tumors (12).

In the present study, comparison of cyclin D1 expression between

11 pericyte-derived tumors and 12 malignant vascular tumors did not reveal a statistically significant difference ($p=0.508$). Therefore, our findings did not produce any data to support the hypothesis in favor of pericyte loss in malignant vascular tumors. However, we believe that more robust results can be obtained with studies using IHC methods where staining is specific to pericytes.

There are studies in the literature demonstrating the effect of estrogen and ER in the pathogenesis of hemangiomas (13). Some studies have shown that estradiol modulates pericyte activity in the brain, thereby improving endothelial integrity (14). However, in our study, we did not detect ER expression in any of the benign and malignant tumors of vascular and pericytic origins, and we found ER expression only in one case of malignant glomus tumor. Estrogen may contribute to the malignant transformation of pericytic tumors by affecting pericytic activity; however, we cannot draw a definitive conclusion in this regard since our study included only one malignant case of pericytic origin.

TAG72 is a high-molecular weight, tumor-associated glycoprotein known to be overexpressed in various carcinomas, including ovarian, breast, and colon tumors (15). The lack of TAG72 expression in normal adult tissues except secretory endometrial tissues has been proven (16). There are only a limited number of studies in the literature investigating TAG72 expression in angiosarcomas (17,18). These studies were conducted with a small

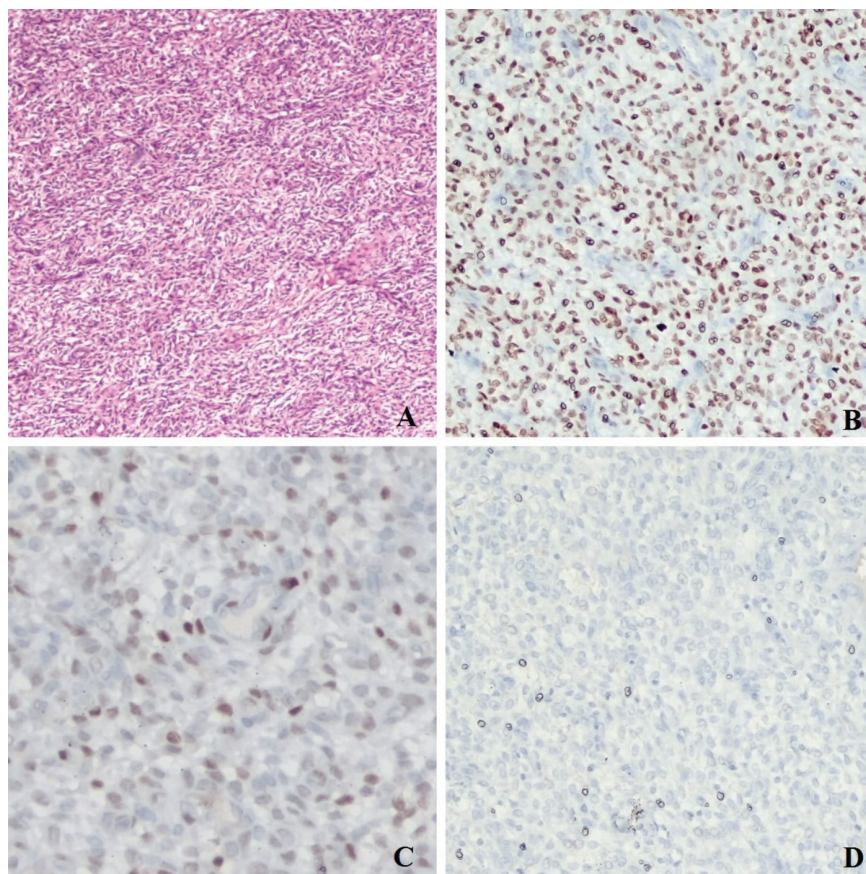


Figure 1. Malignant glomus tumor A: H&E x40, B: Estrogen receptor x100, C: cyclin D1 x100, D: TAG72 x100

sample size and the presence of TAG72 expression was shown in epithelioid angiosarcomas. However, we could not find any study investigating TAG72 expression in benign vascular tumors and pericytic tumors in the literature. Although staining was detected in the control tissue, we did not detect TAG72 expression in any of the benign or malignant tumors included in our study.

Study Limitations

The small sample size was the main limitation of our study. For this reason, statistical evaluation could not be made between subgroups. Further research is needed to evaluate the effect of estrogen on these tumors, especially by means of ER studies to be

Table 2. Cyclin D1 and ER staining, follow-up duration and metastasis status of malignant cases

Diagnosis	Number of cases	Cyclin D1	ER	Metastasis	Follow-up duration	Outcome
Angiosarcoma	1	Low score	Negative	Lung metastasis	12 months	
Angiosarcoma	2	High score	Negative	Null	13 months	
Angiosarcoma	3	High score	Negative	Lung metastasis	24 months	Exitus
Angiosarcoma	4	Low score	Negative	Lung metastasis	8 months	Exitus
Angiosarcoma	5	Low score	Negative	Null	14 months	Exitus
Angiosarcoma	6	Low score	Negative	Null	8 months	
Angiosarcoma	7	Low score	Negative	Null	6 months	Exitus
Angiosarcoma	8	High score	Negative	Null	12 months	Exitus
Malignant glomus	9	Low score	Positive	Null	7 months	
Hemangioendothelioma	10	Negative	Negative	Null	24 months	
Hemangioendothelioma	11	Low score	Negative	Null	24 months	
Hemangioendothelioma	12	High score	Negative	Null	21 months	

ER: estrogen receptor

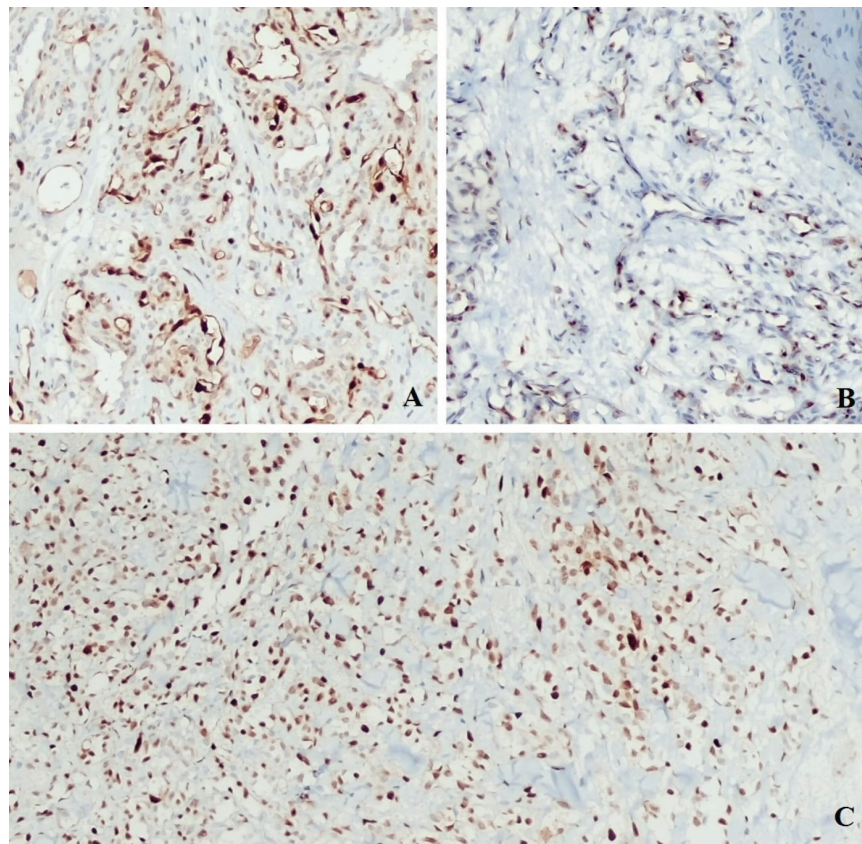


Figure 2. A: Hemangioma cyclin D1 high score x100, B: Hemangioendotelioma, cyclin D1 low score x100, C: Angiosarcoma cyclin D1 high score x100

Table 3. Cyclin D1 expression in benign/malignant vascular and pericytic tumors

Diagnosis	Cyclin D1			Total (n)
	Negative (n)	Low score (n)	High score (n)	
Benign vascular tumors	3	4	10	17
Benign pericytic tumors	1	2	6	9
Malignant vascular tumors	1	6	4	11
Malignant pericytic tumors	0	1	0	1

conducted in larger numbers of malignant glomus tumors, which are malignant pericytic tumors. Finally, we could not investigate pericytic cell loss using an IHC stain specific for pericytes in malignant tumors.

CONCLUSION

We believe that our results on the comparison of cell cycle protein expressions in cutaneous vascular and pericytic tumors shed light for future studies to elucidate the pathogenesis of this group of tumors, which are rarely malignant.

Ethics Committee Approval: The study was approved by the Çukurova University Faculty of Medicine Non-Interventional Clinical Trials Ethics Committee (number: 102, date: 7 august 2020).

Informed Consent: Retrospective study.

Peer-review: Externally peer-reviewed.

Author Contributions: Surgical and Medical Practices - A.M., Ö.Z., S.Ö.; Concept - S.K., K.E.; Design - S.K., K.E., A.M., G.G., S.Ö.; Data Collection and/or Processing - S.K., A.M., G.G.; Analysis and/or Interpretation - S.K., K.E., Ö.Z.; Literature Search - S.K., Ö.Z.; Writing - S.K., K.E., A.M., Ö.Z., G.G., S.Ö.

Conflict of Interest: The authors have no conflict of interest to declare.

Financial Disclosure: The authors declared that this study has received no financial support.

Etik Komite Onayı: Çalışma Çukurova Üniversitesi Tıp Fakültesi Girişimsel Olmayan Klinik Araştırmalar Etik Kurulu tarafından onaylandı (sayı: 102, tarih: 7 Ağustos 2020).

Hasta Onamı: Retrospektif çalışma.

Hakem Değerlendirmesi: Editörler kurulu dışında olan kişiler tarafından değerlendirilmiştir.

Yazar Katkıları: Cerrahi ve Medikal Uygulama - A.M., Ö.Z., S.Ö.; Konsept - S.K., K.E.; Dizayn - S.K., K.E., A.M., G.G., S.Ö.; Veri Toplama veya İşleme - S.K., A.M., G.G.; Analiz veya Yorumlama - S.K., K.E., Ö.Z.; Literatür Arama - S.K., Ö.Z.; Yazan - S.K., K.E., A.M., Ö.Z., G.G., S.Ö.

Çıkar Çatışması: Yazarlar tarafından çıkar çatışması bildirilmemiştir.

Finansal Destek: Yazarlar tarafından finansal destek almadıkları bildirilmiştir.

REFERENCES

- Calonje JE. Vascular tumors. WHO Classification of Tumours Editorial Board. WHO classification of tumours of soft tissue and bone, 5th ed. IARC Press, Lyon (France); 2020. p. 137-56.
- Chapter 21 Benign Vascular Tumors and Malformations, Chapter 22 Hemangioendothelioma: Vascular Tumors of Intermediate Malignancy,

- Chapter 23 Malignant Vascular Tumors, Chapter 25 Perivascular Tumors. Goldblum JR, Folpe AL, Weiss S. Enzinger and Weiss's Soft Tissue Tumors, 7th ed. Canada; 2020. p. 639-765.
- Ribeiro AL, Okamoto OK. Combined effects of pericytes in the tumor microenvironment. *Stem Cells Int* 2015; 2015: 868475.
- Raza A, Franklin MJ, Dudek AZ. Pericytes and vessel maturation during tumor angiogenesis and metastasis. *Am J Hematol* 2010; 85: 593-8.
- Bergers G, Song S. The role of pericytes in blood-vessel formation and maintenance. *Neuro Oncol* 2005; 7: 452-64.
- Weinberg RA. The retinoblastoma protein and cell cycle control. *Cell* 1995; 81: 323-30.
- Khabaz MN, Abdelrahman AS, Butt NS, Al-Maghrabi B, Al-Maghrabi J. Cyclin D1 is significantly associated with stage of tumor and predicts poor survival in endometrial carcinoma patients. *Ann Diagn Pathol* 2017; 30: 47-51.
- Remmele W, Stegner HE. Vorschlag zur einheitlichen Definition eines Immunreaktiven Score (IRS) für den immunhistochemischen Östrogenrezeptor-Nachweis (ER-ICA) im Mammakarzinomgewebe [Recommendation for uniform definition of an immunoreactive score (IRS) for immunohistochemical estrogen receptor detection (ER-ICA) in breast cancer tissue]. *Pathologe* 1987; 8: 138-40.
- Seeliger H, Pozios I, Assmann G, Zhao Y, Müller MH, Knösel T, et al. Expression of estrogen receptor beta correlates with adverse prognosis in resected pancreatic adenocarcinoma. *BMC Cancer* 2018; 18: 1049.
- Choa J, Kima KM, Kimb HC, Leeb WY, Kangc W, Parkc YS, et al. The prognostic role of tumor associated glycoprotein 72 (TAG-72) in stage II and III colorectal adenocarcinoma. *Pathology Research and Practice* 2019; 215: 171-6.
- Fu M, Wang C, Li Z, Sakamaki T, Pestell RG. Minireview: Cyclin D1: normal and abnormal functions. *Endocrinology* 2004; 145: 5439-47.
- Girard N, Marin C, Hélias-Rodzewicz Z, Villa C, Julié C, de Lajarte-Thirouard AS, et al. CARMN-NOTCH2 fusion transcript drives high NOTCH2 expression in glomus tumors of the upper digestive tract. *Genes Chromosomes Cancer* 2021; 60: 723-32.
- Xiao X, Hong L, Sheng M. Promoting effect of estrogen on the proliferation of hemangioma vascular endothelial cells in vitro. *J Pediatr Surg* 1999; 34: 1603-5.
- Dohgu S, Takata F, Yamauchi A, Nakagawa S, Egawa T, Naito M, et al. Brain pericytes contribute to the induction and up-regulation of blood-brain barrier functions through transforming growth factor-beta production. *Brain Res* 2005; 1038: 208-15.
- Ponnusamy MP, Venkatraman G, Singh AP, Chauhan SC, Johansson SL, Jain M, et al. Expression of TAG-72 in ovarian cancer and its correlation with tumor stage and patient prognosis. *Cancer Lett* 2007; 251: 247-57.
- Thor A, Viglione MJ, Muraro R, Ohuchi N, Schlom J, Gorstein F. Monoclonal antibody B72.3 reactivity with human endometrium: a study of normal and malignant tissues. *Int J Gynecol Pathol* 1987; 6: 235-47.
- Sirgi KE, Wick MR, Swanson PE. B72.3 and CD34 immunoreactivity in malignant epithelioid soft tissue tumors. Adjuncts in the recognition of endothelial neoplasms. *Am J Surg Pathol* 1993; 17: 179-85.
- Wenig BM, Abbondanzo SL, Heffess CS. Epithelioid angiosarcoma of the adrenal glands. A clinicopathologic study of nine cases with a discussion of the implications of finding "epithelial-specific" markers. *Am J Surg Pathol* 1994; 18: 62-73.