




Is it Merely Mischief or a Sign? Children with a Foreign Body in the External Acoustic Meatus

Sadece Yaramazlık mı Yoksa Bir İşaret Mi? Çocuklarda Dış Kulak Yolunda Yabancı Cisim

Mehmet Emre Dinç 

Clinic of Otolaryngology, University of Health Sciences Gaziosmanpaşa Taksim Training and Research Hospital, İstanbul, Turkey

Cite this article as: Dinç ME. Is it Merely Mischief or a Sign? Children with a Foreign Body in the External Acoustic Meatus. JAREM 2018; 8: 30-3.

ABSTRACT

Objective: The aim of this study was to determine whether any relationship exists between foreign body in the external acoustic meatus and undiagnosed ear disorders in children.

Methods: In this prospectively designed case-control study, 46 sequential children with foreign body in the external acoustic meatus comprised the study group and 46 children without ear, nose, and throat complaints comprised the control group. Children in both groups underwent tympanometry after the removal of the foreign body. Data included age, sex, the side of the ear with the foreign body, the type of the foreign body, the duration of the presence of the foreign body, details of the removal of the foreign body, and tympanogram type.

Results: Fifteen (32.6%) children in the study group had type A tympanogram, 7 (15.2%) had type C1, 9 (19.6%) had type C2, and 15 (32.6%) had type B. In contrast, 34 (73.9%) children in the control group had type A tympanogram, 5 (10.9%) had type C1, 3 (6.5%) had type C2, and 4 (8.7%) had type B. The percentage of children with type B tympanogram was significantly higher ($p=0.005$) in the study group and that of children with type A tympanogram was significantly higher ($p<0.001$) in the control group.

Conclusion: Clinical and statistical evidences suggest that Eustachian tube dysfunction and serous otitis media cause irritation in children's ears, prompting them to insert something in their ears to ease the irritation. We suggest that all children with foreign body in the external acoustic meatus should be examined by an otologist to prevent delay in diagnosing middle ear disorders. The presence of foreign body in the external acoustic meatus may point to an ear in children and, therefore, should not be ignored.

Keywords: Ear canal, foreign body, otitis media with effusion, eustachian tube, tympanometri, acoustic impedance tests

ÖZ

Amaç: Bu çalışmanın amacı, çocuklarda dış kulak yolunda yabancı cisim ile kulak sorunları arasında bir ilişki olup olmadığının saptanmasıdır.

Yöntemler: Bu prospektif kontrollü çalışmada, çalışma grubu dış kulak yolu kanalında yabancı cisim saptanan 46 çocuk, kontrol grubu ise kulak burun boğaz şikayeti olmayan 46 çocuktan oluşturuldu. Yabancı cisim çıkarıldıktan sonra çalışma grubuna ve kontrol grubuna timpanometri uygulandı. Veriler arasında yaş, cinsiyet, yabancı cisim olan kulak, yabancı cisim tipi, yabancı cismin kaldığı süre, yabancı cismin çıkarılmasına ait ayrıntılar ve timpanometri sonuçları yer aldı.

Bulgular: Çalışma grubundaki çocukların 15'i (%32,6) tip A, 7'si (%15,2) tip C1, 9'u (%19,6) tip C2 ve 15'i (%32,6) tip B timpanometriye sahipti. Buna karşın, kontrol grubundaki çocukların 34'ü (%73,9) tip A, 5'i (%10,9) tip C1, 3'ü (%6,5) tip C2 ve 4'ü (%8,7) tip B timpanometriye sahipti. B tipi timpanometriye sahip çocukların yüzdesi, çalışma grubunda anlamlı olarak daha yüksekti ($p=0,005$) ve A tipi timpanometri yüzdesi kontrol grubunda anlamlı derecede yüksekti ($p<0,001$).

Sonuç: Klinik ve istatistiksel kanıtlar üstaki tüp disfonksiyonu ve efüzyonlu otitis media'nın çocuk kulaklarında tahrişe neden olduğunu ve bu rahatsızlıkları gidermek için kulağına bir şeyler koymalarını sağlayabileceğini göstermektedir. Dış kulak yolları yabancı cisimsi olan tüm çocukların orta kulak problemlerinin teşhisinde gecikmeyi önlemek için bir otolog tarafından görülebilmesini öneriyoruz. Çocuklarda dış kulak yolunda yabancı bir cisim varlığı kulak hastalığına işaret edebilir ve göz ardı edilmemelidir.

Anahtar kelimeler: Kulak yolu, yabancı cisim, efüzyonlu otitis media, üstaki tüpü, timpanometri, akustik empedans testleri

ORCID ID of the author: M.E.D. 0000-0002-9931-8961

INTRODUCTION

Serous otitis media (SOM) is the existence of fluid in the middle ear without middle ear mucosal inflammation. SOM may occur as a spontaneous inflammatory response owing to poor tubal function in the presence of sinonasal disease or after acute otitis media, typically at between 6 months and 4 years of age (1).

Although SOM usually improves, a delay in diagnosis and treatment may result in sequelae and complications because it is a silent process. Therefore, the early and appropriate treatment of this disease is crucial. Complications caused by SOM are divided into three types: speech and language, vestibular, and middle ear disorders. Hearing loss resulting from SOM can lead to improper



speech and language development, which in turn can contribute to an impaired cognitive function and poor school success (2). Studies have shown that vestibular disorders may occur in young children with otitis media (3, 4) and that otitis media causes deterioration in middle ear structures over the long term (5).

In this context, it is meaningful to ask whether the presence of foreign body in a child's ear simply reflects a meaningless pattern of behavior or indicates the presence of ear disorders. It has been suggested that the presence of foreign body in the external acoustic meatus is a marker for SOM in children (6). Therefore, the purpose of this study was to determine whether a relationship exists between the presence of foreign body in the external acoustic meatus and ear disorders.

METHODS

This prospective controlled study was conducted according to the principles of the Declaration of Helsinki at the Department of Otorhinolaryngology University of Health Sciences Gaziosmanpaşa Taksim Training and Research Hospital. The study protocol was approved by the ethics committee of the University of Health Sciences Gaziosmanpaşa Taksim Training and Research Hospital (Approval number: 2016/33). The parents of the children were informed regarding the characteristics of the research, and written consent for the involvement of the children was obtained from all parents.

All children diagnosed with foreign body in the external acoustic meatus were recruited. Children with mental or learning difficulties; those with prior ear surgery; those aged <2 years; and those with a history of oral, palatal, or nasal surgery were excluded, as were those in whom serious bleeding occurred in the external acoustic meatus during the removal of the foreign body.

The control group comprised 46 randomly selected children who came to the pediatric outpatient department with non-ear, nose, and throat (ENT) complaints (e.g., abdominal disorders) and who had no previous history of foreign body in the external acoustic meatus.

Assessment parameters included age, sex, the side of the ear with the foreign body, the type of the foreign body, the duration of the presence of the foreign body, and details of the removal of the foreign body.

We evaluated tympanometry results according to the classification system developed by Zeilhuis et al. (7). This classification system is a type of Jerger's nomenclature (8) and divides the tympanometry results into four subgroups: types A, B, C1, and C2 (Table 1). Types C1, C2, and B were regarded as abnormal (Table 1).

Statistical Analysis

Number Cruncher Statistical System 2007 software (Kaysville, UT, USA) was used for all analyses. The independent samples t-test was used to analyze quantitative data, and Pearson's chi-square test was used to analyze qualitative data. Statistical significance was accepted at $p < 0.05$.

RESULTS

Forty-six children with foreign bodies in the external acoustic meatus comprised the study group, and 46 with non-ENT disorders

comprised the control group. Two children had foreign bodies in both ears. All children were assessed by an experienced otolaryngologist. The sex ratio ($p=0.999$) and mean age ($p=0.865$) did not significantly differ between the groups. There were 26 (56.5%) boys and 20 (43.5%) girls in each group.

Thirty-two (69.6%) children presented within 3 d of foreign body insertion into the external acoustic meatus. Four (8.7%) children applied to the hospital between 4 and 7 d of foreign body insertion, and six (13.0%) applied after 7 d. In four (8.7%) children, there was no information on how long the foreign body was in the ear. Twenty-five (54.3%) children had one foreign body in the right ear, 19 (41.3%) had one foreign body in the left ear, and two (4.3%) had one foreign body in both ears. The most frequent foreign body, i.e., a piece of paper, was found in 18 (39.1%) children; other foreign bodies included beads, various types of plastic pieces, pieces of crayon, and food. In two (4.3%) patients, general anesthesia was required, whereas 44 (95.7%) patients had the foreign body removed as outpatients. Demographic characteristics of patients and controls are summarized in Table 2.

As shown in Table 3, 20 (43.5%) children had a history of previous ear complaints, such as hearing loss, discomfort in the ear, or pain, within the past 6 months.

In the study group, 15 (32.6%) children had type A tympanogram, 7 (15.2%) had type C1, 9 (19.6%) had type C2, and 15 (32.6%) had type B tympanogram. In the control group, 34 (73.9%) children had type A tympanogram, 5 (10.9%) had type C1, 3 (6.5%) had type C2, and 4 (8.7%) had type B tympanogram. There were statistically significant differences in the percentages of children with type A and B tympanogram between the study and control groups. The percentage of children with type B tympanogram was significantly higher ($p=0.005$) in the study group and that

Table 1. Classifications of tympanogram

	Type	Description (middle ear pressure, daPa)
Peaked	A	Between +200 and -99
	C1	Between -100 and -199
	C2	Between -200 and -399
Non-peaked	B	No observable peak between +200 and -600

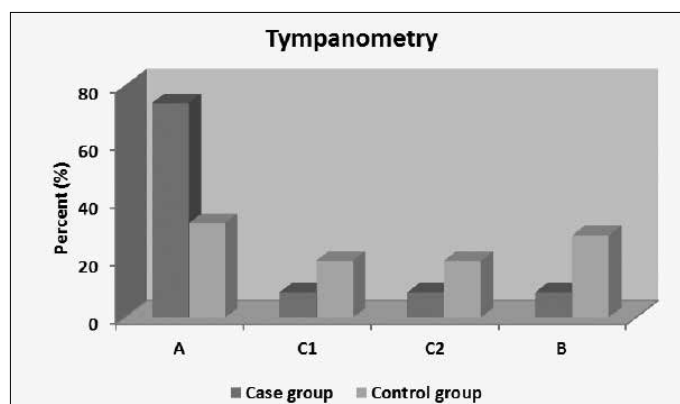


Figure 1. Audiometric assessment

of children with type A tympanogram was significantly higher ($p < 0.001$) in the control group (Table 3, Figure 1).

In the study group, nine children had abnormal findings, including SOM or Eustachian tube dysfunction (ETD), in the ear with the foreign body and a normal opposite ear, and 22 had SOM or ETD in both ears (bilateral foreign bodies were detected in two children). In the remaining 15 patients, all parameters were within the normal limits (Table 4).

DISCUSSION

We found that 67.4% (31/46) children in the study group had different middle ear disorders compared with 26% (12/46) in the control group. There was a statistically significant difference in the percentage of children with type B tympanogram ($p = 0.005$) between the groups. The percentage of children with type C1 tympanograms (15.2%, 7/46) and type C2 tympanograms (19.6%, 9/46) were higher in the study group than in the control group, but these differences were not significant. Twenty (43.5%) pati-

ents in the study group had a previous history of ear complaints and disorders, whereas none in the control group had a history of any ear disorder.

Children with SOM may complain of earache, hearing loss, or tinnitus, and the parents of such children may also report hearing loss, imbalance, or recurrent otitis media. However, in a significant proportion of patients, particularly in young children, SOM may be overlooked because of the mild symptoms of the disease (9). This may explain why complications related to this disease are frequently observed.

Significant hearing loss has been reported to lead to an abnormal progress of speech and language (2, 10, 11) and also bring about poor school success and poor cognitive function (12, 13). Furthermore, SOM can disrupt middle ear structures and cause permanent sequelae, including tympanic membrane perforation, chronic suppurative otitis media, tympanosclerosis, adhesive otitis media, middle ear bone necrosis, retraction pocket, cholesteatoma, and sensorineural hearing loss. These complications are very rare in patients who are appropriately treated (14).

Several studies have revealed the co-occurrence of foreign bodies in the external acoustic meatus and ear disorders. Some studies have revealed that aural foreign bodies may be an indicator of SOM in children. For the first time, in 1972, MacGillivray (15) reported three patients who had SOM presenting as foreign body in the external acoustic meatus. He stated that foreign body in the external acoustic meatus in children may indicate an ear disorder, and children with foreign body in the external acoustic meatus should be evaluated by an ENT physician. Sarkar et al. (6) investigated 74 children with foreign body in the external

Table 2. Demographic and clinical characteristics

	Study group	Control group	p
Age (years)	5.43±2.47	5.34±2.43	0.865 ^a
Sex			
Female	20 (43.5)	20 (43.5)	0.999 ^b
Male	26 (56.5)	26 (56.5)	
Ear with foreign body			
Right	25 (54.3)	-	
Left	19 (41.3)	-	
Both	2 (4.3)	-	
Foreign body type			
Bead	9 (19.6)	-	
Paper	18 (39.1)	-	
Pieces of crayons	6 (13.0)	-	
Various plastic pieces	8 (17.4)	-	
Food	5 (10.9)	-	
Duration of presence of foreign body (days)			
1-3	32 (69.6)	-	
4-7	4 (8.7)	-	
> 7	6 (13.0)	-	
Unknown	4 (8.7)	-	
Removal of foreign body			
Outpatient	44 (95.7)	-	
Under general anesthesia	2 (4.3)	-	

^aIndependent samples t test; ^bPearson chi-square test

Table 3. Audiometric assessment

	Study group	Control group	p
Previous history of ear complaints	20 (43.5)	0	<0.001*
Tympanometry			
Type A	15 (32.6)	34 (73.9)	<0.001*
Type C1	7 (15.2)	5 (10.9)	0.536
Type C2	9 (19.6)	3 (6.5)	0.063
Type B	15 (32.6)	4 (8.7)	0.005*

* $p < 0.05$

Table 4. Foreign body and status of middle ear in patients

Number of patients with foreign body	Status of middle ear
9	Diseased ipsilateral middle ear with normal contralateral middle ear
22 (both ears with foreign body)	Bilateral diseased middle ear
15	Normal middle ear

acoustic meatus and found that 32.4% of these children had type A, 13.5% had type C1, 16.3% had type C2, and 37.8% had type B tympanogram. Ansley and Cunningham (16) achieved similar results in their study and suggested that hearing loss, external acoustic meatus irritation, or otalgia prompted the children to put something in the ear. Schulze (17) reported 698 pediatric patients with foreign bodies in the external acoustic meatus and showed that the frequently presenting concomitant pathology was otitis media, which presented in 5.3% of patients.

CONCLUSION

Our study suggests that ETD and SOM cause irritation in children's ears that prompts them to put something in the ear to ease external acoustic meatus irritation. We propose that all children with foreign body in the external acoustic meatus should be examined by an otologist to prevent the delay in diagnosing middle ear disorders. The results of our study reveal a relationship between foreign body in the external acoustic meatus and ear disorders, and a foreign body in the external acoustic meatus may point to an ear disorder and should not be ignored.

Ethics Committee Approval: Ethics committee approval was received for this study from the ethics committee of University of Health Sciences Gaziosmanpaşa Taksim Training and Research Hospital.

Informed Consent: Written informed consent was obtained from the parents of the patients who participated in this study.

Peer-review: Externally peer-reviewed.

Conflict of Interest: No conflict of interest was declared by the author.

Financial Disclosure: The author declared that this study has received no financial support.

Etik Komite Onayı: Bu çalışma için etik komite onayı Sağlık Bilimleri Üniversitesi Gaziosmanpaşa Taksim Eğitim ve Araştırma Hastanesi'nden alınmıştır.

Hasta Onamı: Yazılı hasta onamı bu çalışmaya katılan hastaların ailelerinden alınmıştır.

Hakem Değerlendirmesi: Dış bağımsız.

Çıkar Çatışması: Yazar çıkar çatışması bildirmemiştir.

Finansal Destek: Yazar bu çalışma için finansal destek almadığını beyan etmiştir.

REFERENCES

1. Rosenfeld RM, Schwartz SR, Pynnonen MA, Tunkel DE, Hussey HM, Fichera JS, et al. Clinical practice guideline: tympanostomy tubes in children. *Otolaryngol Head Neck Surg* 2013; 149: 1-35.
2. Roberts JE, Rosenfeld RM, Zeisel SA. Otitis media and speech and language: meta-analysis of prospective studies. *Paediatrics* 2004; 113: 238-48.
3. Golz A, Netzer A, Angel-Yeger B, Westerman ST, Gilbert LM, Joachims HZ. Effects of middle ear effusion on the vestibular system in children. *Otolaryngol Head Neck Surg* 1998; 119: 695-9.
4. Gravel JS, Wallace IF. Effects of otitis media with effusion on hearing in the first 3 years of life. *Speech Lang Hear Res* 2000; 43: 631-44.
5. Doyle K, Kong YY, Strobel K, Dallaire P, Ray RM. Neonatal middle ear effusion predicts chronic otitis media with effusion. *Otol Neurotol* 2004; 25: 318-32.
6. Sarkar S, Sadhukhan M, Roychoudhury A, Roychaudhuri BK. Otitis media with effusion in children and its correlation with foreign body in the external auditory canal. *Indian J Otolaryngol Head Neck Surg* 2010; 62: 346-9.
7. Zeilhuis GA, Rach GH, Van den Basch A, Van den Broch P. Prevalence of otitis media with effusion: a critical review of literature. *Clin Otolaryngol* 1990; 15: 283-8.
8. Jerger J. Clinical experience with impedance audiometry. *Arch Otolaryngol* 1970; 92: 311-24.
9. Tos M. Epidemiology and natural history of secretory otitis. *Am J Otol* 1984; 5: 459-62.
10. Roberts J, Hunter L, Gravel J, Rosenfeld AR, Berman S, Haggard M, et al. Otitis Media; hearing loss, and language learning: controversies and current research. *J Dev Behav Paediatr* 2004; 25: 110-22.
11. McLaughlin MR. Speech and language delay in children. *Am Fam Physician* 2011; 83: 1183-8.
12. Johnson DL, Swank PR, Owen MJ, Baldwin CD, Howie VM, McCormick DP. Effect of early middle ear effusion on child intelligence at three, five and seven years of age. *J Paediatr Psychol* 2000; 25: 5-13.
13. Augustsoon I, Engstrand I. Otitis media and academic achievements. *Int J Paediatr Otorhinolaryngol* 2001; 57: 31-40.
14. Rosenfeld RM, Kay D. Natural history of untreated otitis media. *Laryngoscope* 2003; 113: 1645-57.
15. MacGillivray N. Glue ear presenting as an aural foreign body: A report of three cases. *J Laryngol Otol* 1972; 86: 167-8.
16. Ansley J, Cunningham M. Treatment of aural foreign bodies in children. *Pediatrics* 1998; 101: 638-41.
17. Schulze S, Kerschner J, Beste D. Paediatric external auditory canal foreign bodies: A review of 698 cases. *Otolaryngol Head Neck Surg* 2002; 127: 73-9.